



EFFECTS OF ETOFENAMATE AND METHYLPREDNISOLONE ON SPINAL CORD INJURY

ETOFENAMATE VE METHYLPREDNİSOLONE'UN OMURİLİK HASARINA ETKİSİ

Burak KAZANCI¹,
Uygur ER²,
Hakan SABUNCUOĞLU³,
Bülent GÜÇLÜ⁴

¹ MD, Assistant Professor of Neurosurgery, Neurosurgery Department, Dr Ridvan Ege Hospital, Medical School of Ufuk University, Ankara.

² MD, Professor of Neurosurgery, Neurosurgery Department, Research and Training Hospital, Medical School, Duzce University, Duzce.

³ MD, Associated Professor of Neurosurgery, Neurosurgery Department, Dr Ridvan Ege Hospital, Medical School of Ufuk University, Ankara.

⁴ MD, Associated Professor of Neurosurgery, Neurosurgery Department, Kartal Research and Training Hospital, Istanbul.

SUMMARY:

This study evaluates the effects of etofenamate on secondary damage following a spinal cord injury and compares the effects with those of methylprednisolone. A total of 31 male Wistar-Albino rats were used. A weight-drop model was utilized for the experimental spinal cord injury and a 50g-cm impact was applied on the spinal cord. Rats were randomly assigned to one of the three study arms (saline, etofenamate 20 mg/kg, methylprednisolone 30 mg/kg). At the sixth hour of injury electrophysiological evaluations were conducted under anesthesia, and then rats were sacrificed for histopathology. Hematoxylin and eosin staining were applied to the specimens and evaluated under light microscopy. Etofenamate revealed more beneficial results in histopathological evaluations when compared with methylprednisolone, but these favorable results have not been confirmed by electrophysiological measurements. Etofenamate may be a promising agent in the medical treatment of spinal cord injury.

Keywords: Etofenamate, methylprednisolone, spinal cord injury, anti-inflammatory

Level of Evidence: Level II, Experimental clinical study

ÖZET:

Bu çalışma omurilik hasarını izleyen ikincil olaylar üzerine etofenamate' in etkisini değerlendirmek ve bu etkiyi metilprednizolon etkisi ile karşılaştırmak amacıyla yapılmıştır. Toplam 31 erkek Wistar-Albino sıçan kullanılmıştır. 50g-cm etkili ağırlık düşürme modeli deneysel omurilik hasarı oluşturmak için kullanılmıştır. Sıçanlar üç çalışma koluna randomize olarak ayrılmışlardır (saline, etofenamate 20 mg/kg, metilprednizolon 30 mg/kg). Hasarın 6.saatinde anestezi altında elektrofizyolojik değerlendirme yapılmış ve sonra histopatolojik inceleme için sıçanlar feda edilmiştir. Hematoksilin-eozin boyaması ile ışık mikroskopu altında değerlendirilmiştir. Etofenamate, metilprednizolon ile karşılaştırıldığında histopatolojik olarak daha faydalı bulunmuştur, fakat bu durum elektrofizyolojik olarak doğrulanamamıştır. Etofenamate omurilik hasarının tedavisinde ümit verici olabilir.

Anahtar sözcükler: Etofenamat, metilprednizolon, omurilik hasarı, antienflamatuvar

Kanıt Düzeyi: Deneysel çalışma, Düzey II

Address: Uygur ER,
Duzce University Medical School,
Department of Neurosurgery
Duzce 81100, Turkey
E-mail: uygurer@gmail.com
Tel: 0505 5892355
Fax: 0380 5421387
Received: 12th July, 2015
Accepted: 27th August, 2015

INTRODUCTION:

Spinal cord injury (SCI) is an untreatable traumatic condition that predominantly affects young males mostly in the second and third decades of life with an increasing annual incidence of 15-40 cases per million^{16,39}. Lifelong treatment and rehabilitation needs of patients along with the social and psychological problems constitute a major burden on both families and healthcare systems¹⁶.

The pathophysiology of SCI has two main stages³¹. The initial primary mechanical trauma results in deterioration of vasculature and cellular membranes of the spinal cord and edema^{10,37}. These lesions are followed by biochemical and metabolic consequences of primary injury that are called secondary degenerative processes and include microvascular lesions, intracellular calcium increase, inflammation, electrolyte imbalance, lipid peroxidation, free radical formation, excitotoxicity by glutamate and apoptosis^{10,15,23,26,29,38}. The secondary processes begin immediately after primary damage and may last for several weeks to expand the area of destruction proportional to the impact of the primary traumatic injury³⁸.

The events in secondary processes are a chain in a continuum that trigger each other. When the integrity of the spinal vasculature has deteriorated, the occurring microhemorrhages cause accumulation of vasoactive amines and hypoxia^{33,42}. Subsequent neuronal injury is related to the release of excess amounts of glutamate which results in calcium influx into the neurons and activation of ryanodine receptors in endoplasmic reticulum to release additional intracellular calcium that activates the apoptotic pathways^{2,13,15,26,27,29,33,35,37}. Another leg of the events during these steps is inflammation. The blood-brain barrier permits the migration of neutrophils and macrophages to the injury field for the clearance of debris, but meanwhile these cells release proteases and free oxygen radicals causing neuronal death by membrane damage²⁵.

Current medical treatments of SCIs aim to protect the neuronal structures against the secondary mechanisms of injury^{17,18}. The most comprehensively evaluated pharmacological agent is methylprednisolone. Early application of this agent on experimental animal SCI models has produced beneficial outcomes, but debates on its efficacy remain^{1,11,32}. This study aims in particular to evaluate the effects of etofenamate, a derivative of N-phenylanthranilic acid, which is an anti-inflammatory agent, by comparing the outcomes with methylprednisolone in an animal model of SCI. Etofenamate exerts its effects over inhibition of prostaglandin synthesis by inhibiting cyclooxygenase. Plasma half-life after parenteral administration is about two hours and urine half-lives vary from 15 to 24 hours¹². The hypothesis of this study is that etofenamate may be an option in the medical treatment of SCIs, depending on the long duration of effect in the organism and its anti-inflammatory properties.

MATERIAL AND METHODS

A total of 31 male Wistar-Albino rats of 220-270gr were included in three study arms randomly. After an experimental SCI in all rats, Group 1 (n=10) received 0.9% saline intraperitoneally (ip), Group 2 (n=11) received 20mg/kg etofenamate ip, and Group 3 (n=10) received 30mg/kg methylprednisolone ip.

Experimental SCI model:

A weight-drop model was used for SCI. After overnight fasting, and following a xylazine HCl (12 mg/kg) and ketamine (75 mg/kg) anesthesia, a dorsal laminectomy was applied at T7-8 level. A 10gr pin at 0.3mm diameter was dropped directly on the spinal cord from a 5cm height (50 g.cm) through a tube. After the SCI, rats took the predetermined medications, or saline, in the study groups mentioned above.

Electrophysiological evaluations:

Spinal evoked potentials (SEP) and motor evoked potentials (MEP) were evaluated under xylazine and ketamine anesthesia at the postoperative sixth hour. For SEP measurements, an active electrode was placed close to the sciatic nerve between the major trochanter and the sciatic ischium, and a recording electrode was placed proximal (T5-6) and then distal (T9-10) to the trauma. The sciatic nerve was stimulated at submaximal level with 1Hz frequency. Stimulus time was 0.1 milliseconds and the stimulus was increased until apparent contraction in the left rear paw. Artifact rejection levels were 500 μ V and 50 μ V in distal and proximal trauma fields respectively, rejection initiation time was 2 milliseconds, stimulus type was single, stimulus repetition time was 2 pulsations per second, amplifier range was 2.5mV, filter was 3Hz-3kHz and sensitivity was 29 μ V for monitor and 5 μ V for store. A mean of 250 recordings was calculated for each subject, and the distances between the active electrodes and the stimulus electrode was recorded (mm). Qualitative evaluations of damaged potentials in posttraumatic SEP measurements were performed according to the modified scales of Zileli et al.⁴³ and Schramm et al.²⁸ Quantitative evaluations included latency (ms) and amplitude (μ V) measurements.

For the MEP recordings, a supramaximal stimulus was applied (maximum 100 mA, 1 ms) in proximal and distal trauma regions. An active electrode was placed on the gastrocnemius muscle and a reference electrode was placed on the Achilles tendon. Amplitude (mV), latency (ms), and velocity (distance between proximal and distal electrodes/negative peak latency difference; $\Delta X/\Delta L$; mm/ms) were calculated.

Histopathology:

Following the electrophysiological evaluations under anesthesia, rats were sacrificed, and approximately 2cm of

spinal cord segment was dissected and fixed in 10% formalin solution. After the paraffin blocking, 4-6 micron sections were stained in hematoxylin-eosin and evaluated by light microscopy. A histopathologist, who was blinded to the intervention evaluated the specimens according to Ivan-Damjanov criteria, and reported the petechial hemorrhages, disseminated hemorrhages, grey and white matter patterns, edema, necrosis, and cystic degeneration^{9,34}.

Ethical statement:

The ethical committees of Ankara Diskapi Yildirim Beyazit Research and Training Hospital of Ministry of Health, and Veterinary Faculty of Ankara University approved this study.

Statistical Analysis:

Descriptive analysis for numerical variables was presented by mean and standard deviation. The quantitative measurements were compared by one-way analysis of variances (ANOVA), and the qualitative measurements were compared by Kruskal-

Wallis test between the study groups. SPSS for Windows 10.0.1 software was used for the analyses. A type I error of 5% was regarded as the level of statistical significance in the analyses.

RESULTS:

Electrophysiological findings:

Findings in the electrophysiological evaluations are presented in Table 1. The qualitative assessments of SEP findings according to Zileli et al.⁴³ and Schramm et al.²⁸ modified scales reveal that damage scores were lower in fields proximal to the trauma in all groups, but the differences regarding qualitative SEP evaluations in proximal and distal regions did not significantly differ between the study groups (p>0.05, for all). Nevertheless, in the proximal field evaluations, Group 3 had the most favorable results, and Group 2 had the lowest scores, and distal field evaluations revealed that groups were similar.

Table-1. Electrophysiological findings of the study groups.				
	Group 1 (saline)	Group 2 (etofenamate)	Group 3 (methylprednisolone)	P
Qualitative SEP				
Distal levels	4.4±1.1	3.7±1.4	4.8±0.4	>0.05
Proximal levels	3.3±2.4	1.6±2.1	3.8±1.8	>0.05
Quantitative SEP				
Distal initial latency (ms)	0.9±0.2	0.9±0.1	0.9±0.1	>0.05
Distal MNP peak latency (ms)	2.6±0.9	2.7±0.9	2.5±0.6	>0.05
Distal MNP amplitude (µV)	81.4±70	25.0±12.7	56.1±67.8	>0.05
Proximal initial latency (ms)	0.9±0.2	1.1±0.3	0.9±0.01	>0.05
Proximal MNP peak latency (ms)	2.9±0.9	2.4±0.3	2.5±0.4	>0.05
Proximal MNP amplitude (µV)	7.3±6.9	6.1±5.2	14.5±14.2	>0.05
MEP				
Distal amplitude (mV)	6.4±1.8	7.6±3.2	6.8±1.9	>0.05
Proximal amplitude (mV)	4.6±2.7	5.9±3.9	6.8±1.6	>0.05
Velocity (mm/ms)	59.8±39.9	65.0±16.5	75.4±21.8	>0.05

SEP, Spinal evoked potentials; MEP, Motor evoked potentials; MNP, Main negative potential

The quantitative SEP evaluations performed on the subjects reflected a normal response or morphological change in the qualitative assessments. In distal regions, initial latency was longer in Group 3, main negative potential (MNP) peak latency was longer in Group 2, and MNP amplitude was higher in Group 1. In proximal regions, initial latency was longer in Group 2, MNP peak latency was longer in Group

1, and MNP amplitude was higher in Group 3. However, the comparisons between study groups did not reveal any significant differences (p>0.05, for all).

MEP evaluations included proximal and distal amplitudes and velocities. The findings reveal that proximal amplitude and velocity values were higher in methylprednisolone group but without statistical significance (p>0.05, for all). Also, distal

amplitude values were higher in Group 2 without statistical significance ($p>0.05$).

Histopathology findings:

The histopathological findings are summarized in Figures 1, 2 and 3. When all the findings are considered together, it can be observed that petechial bleeding was present in all subjects. Widespread hemorrhage was not observed in Group 2, and

was significantly lower in Group 3 than Group 1. Severe loss in the arrangement of grey and white matter was observed in Group 1, but it was lower in Group 2 and 3. Likewise, edema and necrosis were significant in Group 1, but lower in Group 2 and 3. Cystic degeneration was significant in Group 1, rare in Group 3, but not observed in Group 2. As a conclusion, Group 2 (etofenamate) were found to be protected from edema and hemorrhage.

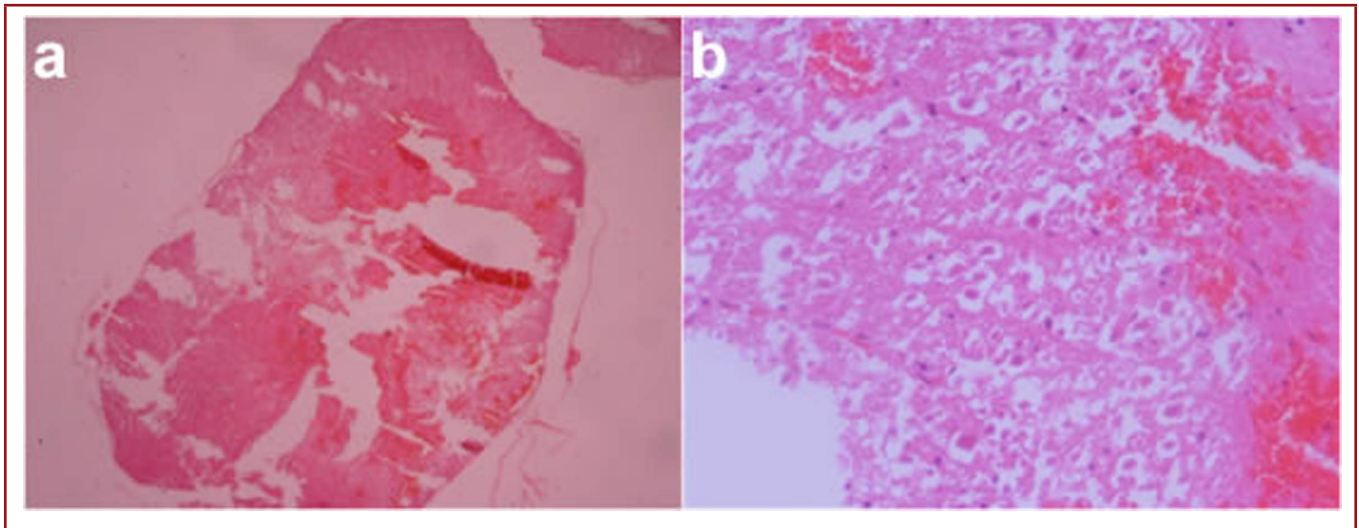


Figure-1. Histopathology findings of Group 1 (saline): grey and white matter pattern loss; widespread hemorrhages and congestion; apparent vascular thrombus formation; apparent edema and cystic degeneration. (A) Widespread hemorrhage, distortion in white and grey matter (H&E, x32). (B) Hemorrhage, necrosis, and cystic degeneration (H&E, x400). Level 2-3 damage according to Ivan-Damjanov Criteria.

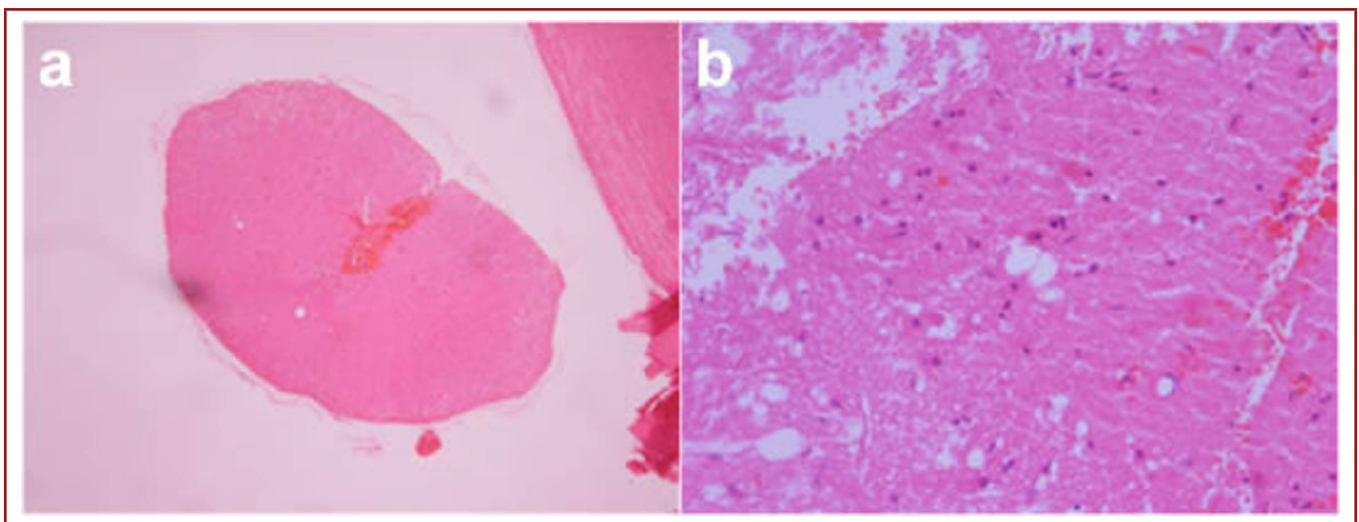


Figure-2. Histopathology findings of Group 2 (etofenamate): minimal loss in grey and white matter pattern; focal hemorrhage and congestion; no thrombus formation; minimum edema, no cystic degeneration. (A) Focal hemorrhage, no edema, necrosis, or distortion (H&E, x32). (B) Congestion and isolated cellular necrosis (H&E, x400). Level 1 damage according to Ivan-Damjanov Criteria.

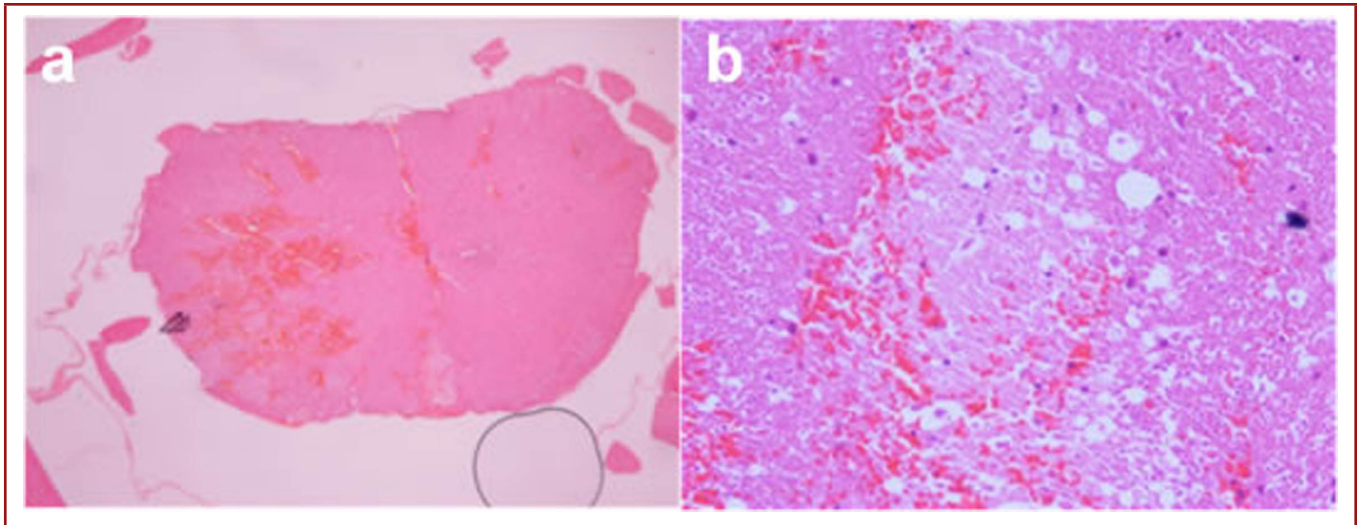


Figure-3. Histopathology findings of Group 3 (methylprednisolone): mild loss in grey and white matter pattern; widespread hemorrhages and congestion; minimum edema, and cystic degeneration. **(A)** Focal hemorrhage and necrosis, separation of grey and white matter, minimum necrosis (H&E, x32). **(B)** Congestion, and isolated cellular necrosis (H&E, x400). Level 1-2 damage according to Ivan-Damjanov Criteria.

DISCUSSION:

This is the first study evaluating the efficacy of etofenamate in traumatic SCI, compared with the well-established methylprednisolone application. The results reveal that etofenamate successfully protected the spinal cord histologically from the effects of secondary damage mechanisms following trauma. Likewise, methylprednisolone also exerted a protective effect against the secondary damage process, but the protective effect was lower than etofenamate.

The histological assessments showed the protective effects of etofenamate, but these findings could not be replicated in electrophysiological evaluations. Nevertheless, qualitative SEP and MEP findings revealed that methylprednisolone was more effective than etofenamate in the protection of the neuronal functions, but this finding did not reach statistical significance.

A substantial number of studies show the efficacy of methylprednisolone in SCI. In many of these studies, favorable results were achieved in animal models of SCI, especially when the medication was initiated in early stages of the injury^{11,32}. The promising efficacy of methylprednisolone on SCI in experimental models led to the development of NASCIS (National Acute Spinal Cord Injury Study). Up to now three large-scale clinical trials were conducted. In NASCIS-I, high-dose and standard dose methylprednisolone were compared, but no difference was found regarding neurological improvement. NASCIS-II emphasized the early administration of methylprednisolone in the first eight hours after injury⁶. Finally, NASCIS-III recommended prolonged maintenance treatment (48 hours) when the initial

intervention is delayed after the first three hours (three to eight hours)⁸.

In 2002, American Association of Neurological Surgeons/ Congress of Neurological Surgeons Joint Section on Disorders of the Spine and Peripheral Nerves published the first guidelines for the management of acute SCI. Through the years, the guidelines were revised and in 2013 the latest revised version was published³⁶. The current guidelines comment on the use of methylprednisolone extensively, and report that the randomized controlled trials which produced Class I data on the topic had many flaws in design and interpretation of the results^{5,7,8}. As a consequence, the previous Class I evidence data were downgraded to Class III in the recent guidelines. The mainstay for this was explained as the results being based on post-hoc analyses and statistical corrections were not used in the methodology.

It is likely that the debate about the administration of methylprednisolone will continue. Meanwhile, novel therapeutic agents are being evaluated in the treatment of SCI. Some of them are Trilazad, uric acid, melatonin, methylene blue, mexilitine, thiopental, β -glucan, N-acetylcysteine, and erythropoietin^{3,4,14,19-22,24,30,40,41}. All of these agents showed beneficial results in SCI, mainly by exerting antioxidant effects. In this study we have evaluated the efficacy of etofenamate on the SCI. This anti-inflammatory agent inhibits the synthesis of prostoglandines, release of bradykinin, histamine, and lysosomal enzymes, and the hyaluronidase activity. Favorable results were obtained in histopathological evaluations in the etofenamate group in our study.

The early histopathological changes after SCI include widespread extravasation of erythrocytes and neutrophils⁴¹. The light microscopic assessments reveal that bleeding was significantly lower in the etofenamate group when compared with the control and methylprednisolone groups. The continuum of the histopathological changes includes deteriorations in neuronal and supporting glial tissues²⁴, but again, in the etofenamate group, we have observed that the cystic degeneration and necrosis were lower. These results showed the neuroprotective effects of etofenamate in an experimental SCI model.

Our study had some limitations. First, we did not perform a neurological examination. Second, our histopathological findings did not correlate with the electrophysiological findings. This discrepancy raises the question of whether histopathology is related to clinical outcomes or not. Also six hours of intervention may not be enough for the effects of the drugs administered. This may also explain the discrepancy between histopathology and electrophysiology. Longer administrations of the drugs may provide more beneficial outcomes.

Our findings regarding the beneficial effects of etofenamate in SCI need further investigation by randomized clinical trials, but preliminary results are promising.

REFERENCES:

1. Akhtar AZ, Pippin JJ, Sandusky CB. Animal studies in spinal cord injury: a systematic review of methylprednisolone. *Altern Lab Anim* 2009; 37: 43-62.
2. Alberdi E, Sánchez-Gómez MV, Marino A, Matute C. Ca(2+) influx through AMPA or kainate receptors alone is sufficient to initiate excitotoxicity in cultured oligodendrocytes. *Neurobiol Dis* 2002; 9: 234-243.
3. Anderson DK, Hall ED, Braughler JM, McCall JM, Means ED. Effect of delayed administration of U74006F (tirilazad mesylate) on recovery of locomotor function after experimental spinal cord injury. *J Neurotrauma* 1991; 8: 187-192.
4. Bardakci H, Kaplan S, Karadeniz U, Ozer C, Bardakci Y, Ozogul C, Birincioglu CL, Cobanoglu A. Methylene blue decreases ischemia-reperfusion (I/R)-induced spinal cord injury: an in vivo study in an I/R rabbit model. *Eur Surg Res* 2006; 38: 482-488.
5. Bracken MB, Shepard MJ, Hellenbrand KG, Collins WF, Leo LS, Freeman DF, Wagner FC, Flamm ES, Eisenberg HM, Goodman JH, Perot PL, Green BA, Grossman RG, Meagher JN, Young W, Fischer B, Clifton GL, Hunt WE, Rifkinson N. Methylprednisolone and neurological function 1 year after spinal cord injury. Results of the National Acute Spinal Cord Injury Study. *J Neurosurg* 1985; 63: 704-713.
6. Bracken MB, Shepard MJ, Collins WF, Holford TR, Young W, Baskin DS, Eisenberg HM, Flamm E, Leo-Summers L, Maroon J, Marshall LF, Perot PL, Piepmeier J, Sonntag, VKH, Wagner FC, Wilberger JE, Winn HR. A randomized, controlled trial of methylprednisolone or naloxone in the treatment of acute spinal-cord injury. Results of the Second National Acute Spinal Cord Injury Study. *N Engl J Med* 1990; 322: 1405-1411.
7. Bracken MB, Shepard MJ, Collins WF Jr, Holford TR, Baskin DS, Eisenberg HM, Flamm E, Leo-Summers L, Maroon JC, Marshall LF, Perot PL, Piepmeier J, Sonntag VKH, Wagner FC, Wilberger JL, Winn HR, Young W. Methylprednisolone or naloxone treatment after acute spinal cord injury: 1-year follow-up data. Results of the second National Acute Spinal Cord Injury Study. *J Neurosurg* 1992; 76: 23-31.
8. Bracken MB, Shepard MJ, Holford TR, Leo-Summers L, Aldrich EF, Fazl M, Fehlings M, Herr DL, Hitchon PW, Marshall LF, Nockels RP, Pascale V, Perot PL Jr, Piepmeier J, Sonntag VK, Wagner F, Wilberger JE, Winn HR, Young W. Administration of methylprednisolone for 24 or 48 hours or tirilazad mesylate for 48 hours in the treatment of acute spinal cord injury. Results of the Third National Acute Spinal Cord Injury Randomized Controlled Trial. National Acute Spinal Cord Injury Study. *JAMA* 1997; 277: 1597-1604.
9. Bunge RP, Puckett WR, Hiester ED. Observations on the pathology of several types of human spinal cord injury, with emphasis on the astrocyte response to penetrating injuries. *Adv Neurol* 1997; 72: 305-315.
10. Cavus G, Altas M, Aras M, Ozgür T, Serarslan Y, Yilmaz N, Sefil F, Ulutas KT. Effects of montelukast and methylprednisolone on experimental spinal cord injury in rats. *Eur Rev Med Pharmacol Sci* 2014; 18: 1770-1777.
11. Chikawa T, Ikata T, Katoh S, Hamada Y, Kogure K, Fukuzawa K. Preventive effects of lecithinized superoxide dismutase and methylprednisolone on spinal cord injury in rats: transcriptional regulation of inflammatory and neurotrophic genes. *J Neurotrauma* 2001; 18: 93-103.

12. Dell HD, Beckermann B, Fiedler J, Kamp R. Renal elimination and metabolism of etofenamate in volunteers after administration of various doses. *Arzneimittelforschung* 1990; 40: 311-316.
13. D'Orsi B, Bonner H, Tuffy LP, Düssmann H, Woods I, Courtney MJ, Ward MW, Prehn JH. Calpains are downstream effectors of bax-dependent excitotoxic apoptosis. *J Neurosci* 2012; 32: 1847-1858
14. Genovese T, Mazzon E, Muià C, Bramanti P, De Sarro A, Cuzzocrea S. Attenuation in the evolution of experimental spinal cord trauma by treatment with melatonin. *J Pineal Res* 2005; 38: 198-208.
15. Gomes-Leal W, Corkill DJ, Picanço-Diniz CW. Systematic analysis of axonal damage and inflammatory response in different white matter tracts of acutely injured rat spinal cord. *Brain Res* 2005; 1066: 57-70.
16. Hall ED, Springer JE. Neuroprotection and acute spinal cord injury: a reappraisal. *NeuroRx* 2004; 1: 80-100.
17. Hamann K, Durkes A, Ouyang H, Uchida K, Pond A, Shi R. Critical role of acrolein in secondary injury following ex vivo spinal cord trauma. *J Neurochem* 2008; 107: 712-721.
18. Hurlbert RJ. Methylprednisolone for the treatment of acute spinal cord injury: point. *Neurosurgery* 2014; Suppl. 1: 32-35.
19. Kaptanoglu E, Caner HH, Sürücü HS, Akbiyik F. Effect of mexiletine on lipid peroxidation and early ultrastructural findings in experimental spinal cord injury. *J Neurosurg* 1999; Suppl. 2: 200-204.
20. Kaptanoglu E, Sen S, Beskonakli E, Surucu HS, Tuncel M, Kilinc K, Taskin Y. Antioxidant actions and early ultrastructural findings of thiopental and propofol in experimental spinal cord injury. *J Neurosurg Anesthesiol* 2002; 14: 114-122.
21. Kayali H, Ozdag MF, Kahraman S, Aydin A, Gonul E, Sayal A, Odabasi Z, Timurkaynak E. The antioxidant effect of beta-Glucan on oxidative stress status in experimental spinal cord injury in rats. *Neurosurg Rev* 2005; 28: 298-302.
22. Kaynar MY, Erdiñçler P, Tadayyon E, Belce A, Gümüştas K, Ciplak N. Effect of nimodipine and N-acetylcysteine on lipid peroxidation after experimental spinal cord injury. *Neurosurg Rev* 1998; 21: 260-264.
23. Liu NK, Zhang YP, Titsworth WL, Jiang X, Han S, Lu PH, Shields CB, Xu XM. A novel role of phospholipase A2 in mediating spinal cord secondary injury. *Ann Neurol* 2006; 59: 606-619.
24. Rawe SE, Lee WA, Perot PL Jr. The histopathology of experimental spinal cord trauma. The effect of systemic blood pressure. *J Neurosurg* 1978; 48: 1002-1007.
25. Rosado IR, Lavor MS, Alves EG, Fukushima FB, Oliveira KM, Silva CM, Caldeira FM, Costa PM, Melo EG. Effects of methylprednisolone, dantrolene, and their combination on experimental spinal cord injury. *Int J Clin Exp Pathol* 2014; 7: 4617-4626.
26. Sánchez-Gómez MV, Alberdi E, Ibarretxe G, Torre I, Matute C. Caspase-dependent and caspase-independent oligodendrocyte death mediated by AMPA and kainate receptors. *J Neurosci* 2003; 23: 9519-9528.
27. Sánchez-Gómez MV, Alberdi E, Pérez-Navarro E, Alberch J, Matute C. Bax and calpain mediate excitotoxic oligodendrocyte death induced by activation of both AMPA and kainate receptors. *J Neurosci* 2011; 31: 2996-3006.
28. Schramm J, Krause R, Shigeno T, Brock M. Experimental investigation on the spinal cord evoked injury potential. *J Neurosurg* 1983; 59: 485-492.
29. Schwartz G, Fehlings MG. Secondary injury mechanisms of spinal cord trauma: a novel therapeutic approach for the management of secondary pathophysiology with the sodium channel blocker riluzole. *Prog Brain Res* 2002; 137: 177-190.
30. Scott GS, Cuzzocrea S, Genovese T, Koprowski H, Hooper DC. Uric acid protects against secondary damage after spinal cord injury. *Proc Natl Acad Sci USA* 2005; 102: 3483-3488.
31. Stirling DP, Khodarahmi K, Liu J, McPhail LT, McBride CB, Steeves JD, Ramer MS, Tetzlaff W. Minocycline treatment reduces delayed oligodendrocyte death, attenuates axonal dieback, and improves functional outcome after spinal cord injury. *J Neurosci* 2004; 24: 2182-2190.
32. Taoka Y, Okajima K, Uchiba M, Johnno M. Methylprednisolone reduces spinal cord injury in rats without affecting tumor necrosis factor-alpha production. *J Neurotrauma* 2001; 18: 533-43.
33. Tator CH, Fehlings MG. Review of the secondary injury theory of acute spinal cord trauma with emphasis on vascular mechanisms. *J Neurosurg* 1991; 75: 15-26.
34. Tator, CH. Biology of neurological recovery and functional restoration after spinal cord injury. *Neurosurgery* 1998; 42: 696-707; discussion 707-708.
35. Thorell WE, Leibrock LG, Agrawal SK. Role of RyRs and IP3 receptors after traumatic injury to spinal cord white matter. *J Neurotrauma* 2002; 19: 335-342.

-
36. Walters BC, Hadley MN, Hurlbert RJ, Aarabi B, Dhall SS, Gelb DE, Harrigan MR, Rozelle CJ, Ryken TC, Theodore N. American Association of Neurological Surgeons; Congress of Neurological Surgeons: Guidelines for the management of acute cervical spine and spinal cord injuries: 2013 update. *Neurosurgery* 2013; Suppl. 1: 82-91.
 37. Wang C, Nguyen HN, Maguire JL, Perry DC. Role of intracellular calcium stores in cell death from oxygen-glucose deprivation in a neuronal cell line. *J Cereb Blood Flow Metab* 2002; 22: 206-214.
 38. Wilson JR, Forgione N, Fehlings MG. Emerging therapies for acute traumatic spinal cord injury. *CMAJ* 2013; 185: 485-492.
 39. Wyndaele M, Wyndaele JJ. Incidence, prevalence and epidemiology of spinal cord injury: what learns a worldwide literature survey? *Spinal Cord* 2006; 44: 523-529.
 40. Yazihan N, Uzuner K, Salman B, Vural M, Koken T, Arslantas A. Erythropoietin improves oxidative stress following spinal cord trauma in rats. *Injury* 2008; 39: 1408-1413.
 41. Zhang Z, Krebs CJ, Guth L. Experimental analysis of progressive necrosis after spinal cord trauma in the rat: etiological role of the inflammatory response. *Exp Neurol* 1997; 143: 141-152.
 42. Zhao J, Zhang S, Wu X, Huan W, Liu Z, Wei H, Shen A, Teng H. KPC1 expression and essential role after acute spinal cord injury in adult rat. *Neurochem Res* 2011; 36: 549-558.
 43. Zileli M, Taniguchi M, Cedzich C, Schramm J. Vestibulospinal evoked potential versus motor evoked potential monitoring in experimental spinal cord injuries of cats. *Acta Neurochir (Wien)* 1989; 101: 141-148.