

REDUCTION AND STABILIZATION OF SPONDYLOLISTHESIS USING ALICI SPINAL INSTRUMENTATION

E. Alici, N. Erel, E. Serin, H. Tatari

*From Department of Orthopaedic Surgery, University of Dokuz Eylul
İzmir - TURKEY*

In this study, the preliminary results of the surgical treatment of spondylolisthesis using Alia Instrumentation that we have started to use in the recent year in the Orthopaedics and Travmatology Clinics of Dokuz Eylil and Ege Universities have been reported. Eighteen patients with spondylolisthesis were treated. Their ages ranged from 18 to 73 years, with a mean of 50 years. The length of follow-up ranged from 3 to 12 months with a mean of 6 months. The slip amount of the patients was between grade 1 and grade 2 according to Meyerding. On the other hand, according to Taillard the average percentage of slip was 20 % in 15 patients and 40 % in 3 patients. Complete reduction has been obtained by using Alici Instrumentation in all patients.

Key Words : Spondylolisthesis, Alici Spinal Instrumentation.

Spondylolisthesis has been described since the 18th century and from the beginning of 20th century important advances have been reported in its treatment.

In order to stop further slipping, various operations have been described : Posterior fusion with tibial grafts (1); an H-graft (3); cancellous bone grafts; posterolateral fusion; posterior intervertebral fusion and anterior fusion. Albee, Hibbs, Bosworth, Kellogg-Speed, Cloward, Gill-morning, Takcda and some other researchers are the ones who developed and used these techniques (1,2,3,5,7,8).

Harrington (1969) (7,8) was the first one who settled the reduction and stabilization with internal fixation; and then most workers have adapted Harrington Instrumentation to their own methods. (Scaglietti, Frontino and Bortolozzi 1976; De Wald et al 1981; Sijbrandij 1983) (5,10, 11, 12). The using of the pedicular screw was first described by Dwyer. Then Cotrell, Dick and others have developed their own methods by stabilization with pedicular screw (4, 6, 9, 13).

In the method developed by Alici, distraction with the threaded rods and hooks and reduction with a pedicular screw has been obtained.

MATERIAL AND METHODS :

In the last one year 18 patients with spondylolisthesis were treated by this method in the Orthopaedics

and Travmatology Clinics of Dokuz Eylil University and Ege University. There were 16 females and 2 males. Their ages ranged from 18 to 73 years with a mean of 50 years. Spondylolisthesis was present at L4/5 in 8 patients and L5/S1 in 10 patients.

All patients were suffering from severe and progressive low back pain. Five patients presented with the aschill reflex absence, 2 with aschill and patella reflex absence, 6 with hipoaesthesia on L5 and SI dermatomes, 4 with tight hamstrings and 2 with atrophy in thigh.

Roentgenographic evaluation was performed according to Meyerding and Taillard criteris (14). According to Meyerding the slip amount was Grade 1 in 15 patients and grade 2 in 3 patients. In Taillard's criteria, the percentage of slip was minimum 15 % and maximum 25 % with a mean of 20 % in 15 patients and 40 % in 3 patients.

In the actiologic evaluation, the reason was spondylolisis in 14 patients, degenerative changes in 1 patient, congenital reason in 2 patients and trauma in 1 patient.

Alicic instrument is an instrument with the upper part threaded and the lower part shaped as a square and bent 30 degrees; the distal part confirmed with the lower hook, bent 10 degrees and shaped as a square. The upper hook is the standard lamina hook and by inserting the threaded part of the rod and turning the nut, distraction is performed. The lower hook with the rod socket shaped as a square (to prevent rotation), is designed large and deep for the hook wing to place on to the sacral crest. The screw director apparatus is a rectangular prism with 2 holes perpendicular to each other. One of the holes is square - shaped and placed on

E. Alici, Clinical Professor,
N. Erel, Research Fellow, Orthopaedic Surgeon,
E. Serin, H. Tatari Research Fellow
Department of Orthopaedic Surgery and Traumatology,
Dokuz Eylil University Faculty of Medicine
IZMIR-TURKEY

the lower part of the rod shaped as a square. The second hole, left outside and bent 12 degrees inward, is round and directs the screw to the pedicle and makes the fixed point in the reduction. There are two 60 mm long spongios screws.

Operative Technique : A medial longitudinal incision is made. The paravertebral muscles are stripped off in order to expose the area between sacral crest and the lamina that belongs to the second vertebra above the slipped vertebra. If there is stenosis in the spinal canal and/or the lamina is very instable, then total laminectomy is performed. Spinal canal is checked. The lower hook is placed on the nearest part of the sacral crest to the midline. The upper hook is fixed to the second vertebral lamina above the slipped one. One screw socket and one nut are applied to the rod and the rod is inverted in the hooks. By screwing the nut, distraction is provided.

The distraction is controlled under x-ray. Then, the pedicle of the slipped vertebra is identified and the entrance hole of the screw is prepared. Under scopy control, the screw is inserted in its socket and in the pedicle.

After the head of the screw is placed into the socket, with every squeezing action, the slipped vertebra will be pulled to the rod. This will provide the reduction. After the stabilization and reduction are obtained, posterior interbody fusion or posterior fusion or both can be performed according to the case. After 6 week period of bedrest, mobilization is permitted with a lumbo-sacral brace. The hospitalization period is approximately 2 weeks.

Posterior fusion to 10 patients, anterior fusion to 5 patients and anterior + posterior fusion to 3 patients were applied. Laminaectomy was performed in the cases in which stenosis and radix squeezing were identified in the CT scans and radicular signs were presented clinically.

In the older and osteoporotic patients, in the more instable cases, anterior and posterior fusion together has been applied. The operation time average was 2 hours and 45 minutes and the average blood loss was 2 units.

RESULTS :

The preliminary results of the cases were followed minimum 3 months, maximum 12 months and average 6 months. We identified regression or dissapearing of the low back pain in all patients. The symptoms of the patients presenting reflex absence, remianed the

same. Six patients suffering from hypoaesthesia pleasure for the patients to ged rid of their low back pain, which was the main problem.

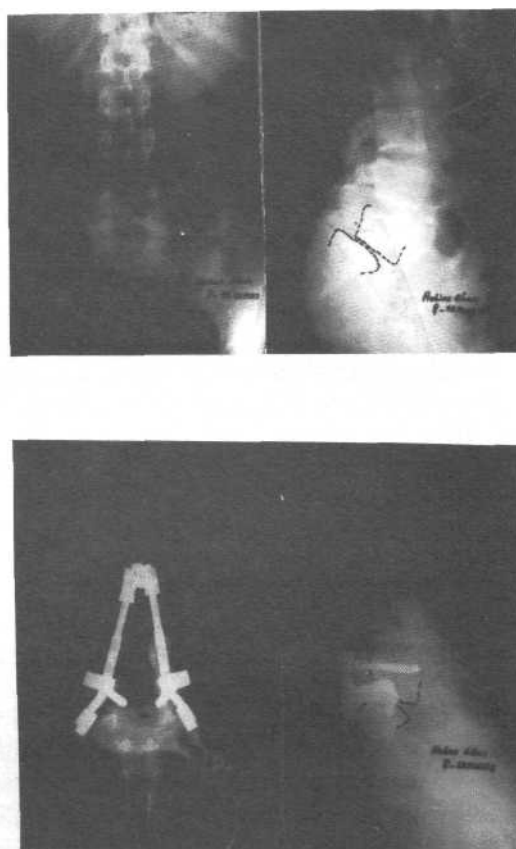


Fig. 1-A : Pre-operative A/P and lateral x-rays.
Fig. 1-B : Post-operative A/P and lateral x-rays.

In the radiological controls, the percentage of slip was 0 in all patients according to Taillard and Meyerding. There were no breaking and failure in the instruments.

In the postoperative period, in 3 patients superficial skin infection, and in 1 patient deep skin infection developed. The superficial infections recovered with suitable antibiotherapy. The patient having deep skin infection has been operated again. In the operation, it was determined that the source of the infection was the piece of spongell put in the operation area. After spongell has been removed and the patient recovered with suitable antibiotherapy. No need to remove the instruments and good results have been obtained.

DISCUSSION :

In the treatment of spondylolisthesis, reduction and stabilization are the two main factors. With the methods used until now, reduction has been tried to provide with distraction. This is effective to some degree. Because, the distraction force has affected secondarily the slipped vertebra. But in our method, both a determined reduction in this area by distraction and confortability in the vertebra, has been provided; and with the pedicular screw, by applying direct force to the slipped vertebra, reduction has been obtained. In Dwyer's pedicular fixation, during the pedicle's direct force to the vertebra, the support points of the screws are dependent on the cable's tension and can not be very effective. In our method, the screw is placed on the posterior rod supported with the upper and lower strong bone structures and takes its support from here. By squeezing the screw, the slipped vertebra is pulled to the rod and this is an effective reduction method by using direct force.

Therefore, the slipped vertebra is screwed to the posterior rod and this prevents the possible reduction loss in the stabilization. During the operation, the possibility of laminaectomy and control of the spinal canal and using different methods like anterior, posterior, ant + post fusion are the factors that increase the surgical efficiency.

The operation method is comfortable as the Harrington system. In addition, its easy and needs a short period of time for the need of ability of placing the pedicle.

We do not believe that the screw inserted to the sacral area are successful because the cortex is very thin, and the cancellous bone is very loose. Thus, Roy-Camille et al have reported 100 %, Dick has reported 69 %, Steffee et al have reported 100 %, McQueen et al have reported 100 % successful cases (6, 9, 13).

In our literature researches we were not confronted with hook + screw combination which are used in a any instrumentation. We believe that the Alici instrumentation is a new operative treatment of spondylolisthesis and is very successful.

REFERENCES :

- 1 . Albee, F.H. : Transplantation of a portion the tibia into the spine for Pott's disease. A preliminary report. J. Am. Med. Assoc. 75, 885-886 (1911)
- 2 . Alici, E. : A new method in the treatment of spondylolisthesis using anterior fusion. Journal of Ege University. V. 23 No: 2 619, 1984.
- 3 . Bosworth, M.D., Fielding, J. w., Dewarrest, L., Bonaquist, J. : Spondylolithesis. A critical review of consecutive series of cases treated by arthrodesis. J. Bone Joint Surg. (Am) 37, 767-786, 1955
- 4 . Cotrell, Y., Dubousset, J. : New Universal Instrumentation in Spinal Surgery. Clin. Orthop. 227 : 10-20, 1988.
- 5 . De Wald, R.L., Faut, M.M., Taddonio, R.F., Neuwirth, M.G. : Severe lumbo-sacral spondylolisthesis in adolescents and child : reduction and staged circumferential fusion J. Bone joint surg. (Am) 63-A : 619-26, 1981.
- 6 . Dick, W. : The "fixateur interne" as a versatile implant for spine surgery. Spine V. 12 N. 9 882-900, 1987.
- 7 . Harrington, P.R., Tullos, H.S. : Reduction of severe spondylolisthesis in children. South Med. J. 62 (1) 1-7, 1969.
- 8 . Harrington, P.R., Dickson, J.H.: Spinal Instrumentation in the treatment of severe progressive spondylolisthesis. Clin. Orthop 117 : 157-63, 1976.
- 9 . McQueen, M.M., Court-Brown, C, Scott, J.H.S. : Stabilization of spondylolisthesis using Dwyer instrumentation. J. Bone Joint Surg. (Br) Vol. 68-B No: 2 185-188, 1986.
- 10 . Scaglietti, O., Frontino, G., Bartolozzi, P., Technique of anatomical reduction of lumbar spondylolisthesis and its surgical stabilization. Clin. Orthop. 117 : 164-75, 1976.
- 11 . Scaglietti, O., Bortolozzi, P., Alici, E. : Spondylolisthesis and its treatment, Journal of Ege University V. 15 No. : 3 477-489, 1976.
- 12 . Sijbrondij S. : Reduction and Stabilization of Severe Spondylolisthesis. A report of three cases. J. Bone Joint Surg. (Br) 1983 : 65-B : 40-2
- 13 . Steffee, A.D., Sitkowski, D.J., Reducation and Stabilization of Grade IV Spondylolisthesis. Clin. Orthop. N. 227. 82-89, 1988.
- 14 . Taillard, W. : Les spondylolisthesis. Paris, Masson et Cie, Ed. 1957.