



BALLOON KYPHOPLASTY IN OSTEOPOROTIC PATIENTS WITH SPONTANEOUS VERTEBRAL COMPRESSION FRACTURES

SPONTAN VERTEBRA KIRIĞI OLAN OSTEOPOROTİK HASTALARDA BALON KİFOPLASTİ

Emre DEMİRCAY¹,
Atilla KIRCELLİ²

¹ Department of Orthopedic Surgery,
Baskent University, Istanbul.

² Department of Neurosurgery, Baskent
University, Istanbul.

SUMMARY

Objective: The purpose of this study is to assess the outcomes of our patients who underwent balloon kyphoplasty for spontaneous osteoporotic vertebral fractures regarding pain relief, correction of the vertebral body height, and complications such as adjacent segment vertebral fractures

Material and Methods: We retrospectively evaluated 63 consecutive patients (74 vertebral bodies) with vertebral body compression fracture who were treated by balloon kyphoplasty. Patients' body mass index (BMI), bone mineral density (BMD), level(s) of the fractured vertebrae, visual analog scale (VAS) for pain intensity were noted. Local kyphosis angle (KA), and the rate of vertebral height loss (VHL) were measured. Oswestry disability index (ODI) was used to assess the disability. All the patients had a minimum follow-up of 12 months

Results: KA and VHL as well as VAS and ODI scores significantly improved at the final follow-up ($p<0.05$, $p<0.001$ respectively). There were cement leakage in 5 procedures (6.7 %) and 11 (14.8 %) adjacent segment fractures (ASF) were detected during the follow-up.

Conclusion: Balloon kyphoplasty is an effective and safe procedure that can provide early pain relief, improve function and correct the deformity in spontaneous osteoporotic vertebral body fractures.

Keywords: Osteoporosis, osteoporotic spinal fractures, surgical treatment kyphoplasty

Level of evidence: Retrospective clinical study, Level III.

ÖZET

Giriş: Bu çalışmanın amacı balon kifoplasti yapılan spontan osteoporotik vertebra kırıklı hastaların; ağrının giderilmesi, vertebral gövde yüksekliğinin düzeltilmesi ve komşu segment kırıkları gibi komplikasyonlar açısından değerlendirilmesidir.

Materyal-Metot: Balon kifoplasti ile tedavi edilmiş vertebral gövde kompresyon kırıklı 63 hasta (74 vertebral seviye) geriye dönük olarak incelendi. Hastaların vücut kitle indeksi (BMI), kemik mineral yoğunluğu (BMD), kırık vertebraların seviyeleri kaydedildi. Lokal kifoz açısı (KA), ve vertebral gövde yükseklik kayıp oranı (VHL) ölçüldü. Klinik değerlendirmede ağrı için görsel analog çizelge (VAS) skorları ve Oswestry sakatlık skoru (ODI) kullanıldı. Tüm hastaların en az 12 aylık takipleri kaydedildi.

Sonuçlar: Hem KA ve VHL, hem de VAS ve ODI skorlarında son kontrolde anlamlı olarak düzelme görüldü ($p<0.05$, $p<0.001$). Takip süresince 5 (% 6.7) seviyede sement kaçağı ve 11 (% 14.8) komşu segment kırığı (ASF) tespit edildi.

Sonuç: Balon kifoplasti, osteoporotik vertebral gövde kırıklarında, erken ağrı kontrolü, fonksiyonun geri kazanımı ve deformiteyi düzeltmede etkili ve güvenli bir yöntemdir.

Anahtar kelimeler: Osteoporoz, osteoporotik omurga kırığı, cerrahi tedavi, kifoplasti

Kanıt düzeyi: Retrospektif klinik çalışma, Düzey III

Address: Emre Demirçay,
Oymacı S7, Altunizade, Uskudar, 34662,
Istanbul, Turkey

Phone: + 90 532 433 54 69

Fax: + 90 216 651 98 58

e-mail: emredemircay@gmail.com

Received: 11th December, 2016.

Accepted: 16th February, 2017.

INTRODUCTION

Spontaneous vertebral body fractures are an increasing concern among senior population. These fractures can cause pain, a decrease in quality of life, kyphosis that may lead to respiratory insufficiency, and limitation of mobilization. Balloon kyphoplasty is a minimally invasive and effective technique for reducing pain and decreasing kyphotic deformity. It was introduced by Garfin et al. to restore vertebral height and correct kyphotic deformity and maintaining the correction by applying polymethylmethacrylate (PMMA) (5-6). The main goal in the treatment of osteoporotic vertebra fractures is to relieve pain, regain functions of daily living and halt the progression of osteoporosis. It can be performed in patients either with neoplastic, traumatic and osteoporotic fractures.

Conservative treatment of VCF usually consists of bed rest, analgesics and bracing.

Unfortunately, prolonged immobilization may exacerbate osteoporosis that may further predispose osteoporotic vertebral compression fractures (8,24-25). However, open surgery with implants pose higher risk, especially for the osteoporotic patients with associated co-morbidities (13).

The purpose of this study is to assess the outcomes of our patients who underwent balloon kyphoplasty for spontaneous osteoporotic vertebral fractures regarding pain relief, correction of the vertebral body height, and complications such as adjacent segment vertebral fractures. The patients were evaluated in terms of pain relief, correction of the deformity, and complications such as adjacent segment vertebral fractures.

Balloon kyphoplasty is a valuable tool for the patients with VCF when conservative treatment has failed. It provides sustainable improvement to the patients' pain and disability.

MATERIALS AND METHODS

We retrospectively evaluated 63 consecutive patients (74 vertebral bodies) with vertebral body compression fracture who were treated by balloon kyphoplasty between September 2014 and October 2016 (Table 1). Patients mean age was 78.5 ± 9.1 years. There were 15 male (23.8 %) patients and 48 (76.2 %) female patients in our study. Female: Male ratio was 3:1.

All of the patients had X rays and MRI scans of the involved area. Patients' body mass index (BMI), bone mineral density (BMD), level(s) of the fractured vertebrae, visual analog scale (VAS) for pain intensity were noted. Local kyphosis angle (KA), and the rate of vertebral height loss (VHL) were measured on the lateral plain radiographs. BMD was measured at the lumbar spine (L1-L4) by dual-energy radiograph absorptiometry (DEXA). An average BMD value was calculated for each subject by averaging values from L1 to L4, excluding those vertebrae where the augmentation

procedure had been performed, and the T scores were noted. Oswestry disability index (ODI) was used to assess the disability (Table-1) (4).

All the patients had minimum 2 weeks of conventional treatment such as bed rest, NSAID, and bracing before the procedure. The indications for the procedure were severe pain due to acute (> 2 weeks) or sub-acute (2-8 weeks) osteoporotic vertebral body compression fracture and kyphotic deformity of more than 30°. The local kyphosis angle was measured by Cobb method (Figure 1). The rate of vertebral body height loss (VHL) was estimated by calculating mean anterior vertebral body height of the adjacent vertebrae and the ratio of the anterior vertebral height of the fractured vertebra to this average height. Bone edema indicating acute fracture was confirmed with short tau inversion recovery sequences (STIR) of the magnetic resonance imaging (Figure-2) (24).

Table-1. Presentation and clinical characteristics of the 63 patients (74 cases). KA: Kyphosis angle, VHL: Vertebral height loss, VAS: Visual analog scale for pain assessment, ODI: Ostrowski disability index.

T6	1 (1.4%)
T7	1 (1.4%)
T9	1 (1.4%)
T10	4 (5.4%)
T11	2 (2.7%)
T12	18 (24.3%)
L1	14 (18.9%)
L2	9 (12.2%)
L3	14 (18.9%)
L4	6 (8.1%)
L5	4 (5.4%)
BMI	26 ± 3.6
KA (degrees)	15.3 ± 11.4
VHL (%)	53.6 ± 13.4
T score:	-3.2 ± 1.26
VAS	8.1 ± 0.8
ODI	66.5 ± 7.1

The patients who had previous vertebroplasty, kyphoplasty, an osteoporotic vertebral collapse higher than 90%, or the patients with neurological deficit, bleeding disorders, unstable fractures due to posterior element involvement were excluded. Also the patients with a malignant disease, systemic or spinal infections were excluded.

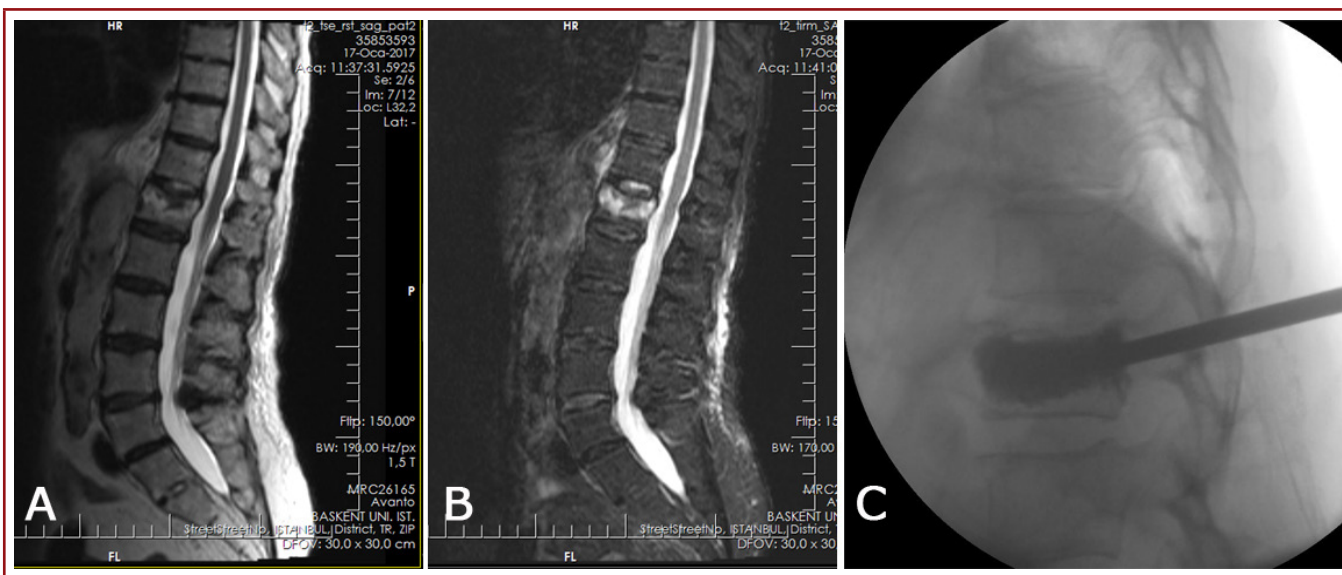


Figure-1. A) Preoperative T2A and B) STIR magnetic resonance images of a patient with L1 compression fracture, C) Lateral intraoperative C-arm image of the same patient.

Surgical technique

All the procedures were done with sedation and local anesthesia in prone position. Cephazoline sodium 1gr IV was used as prophylaxis. The fractured vertebra was centered on the AP and lateral C-arm projections. Two 11-gauge Jamshidi needles were inserted percutaneously into both pedicles of the fractured vertebra. Two guide pins were inserted through the Jamshidi needles into the two thirds of the vertebral body and then two inflatable bone tamps were advanced into the fractured vertebral body. The balloons were inflated simultaneously under C arm observation. A volume of 3-4 cm³ was created in the vertebral body while maintaining pressures below 200 pound/inch² in the balloons. A matching volume of polymethylmethacrylate (PMMA) was injected through the pedicles. Postoperative anterior-posterior and lateral X-rays were ordered to check for complications and cement leakage.

Patients were asked to attend the follow-up visits on the 3rd, 6th and 12th months. BMD of the patients were obtained on the first follow-up visit. All follow-up visits consisted of physical examinations, VAS assessments for pain, ODI and x-rays to assess the treated and adjacent vertebrae. The same investigator did all radiological measurements.

All the patients had a minimum follow-up of 12 months; the mean follow-up period was 23.4 ± 5.2 months.

Statistical Analysis

Statistical analyses were performed using SPSS software version 21 (Armonk, NY). The variables were investigated using visual (histograms, probability plots) and analytical

methods (Kolmogorov-Smirnov / Shapiro-Wilk's) to determine whether they are normally distributed. Descriptive analyses were presented using medians and interquartile range (IQR) for the non-normally distributed and ordinal variables. Since the KA and VHL measurements were not normally distributed; nonparametric tests were conducted to compare these parameters, as well as to compare the ordinal variables. The Mann-Whitney U test was used to compare preoperative versus postoperative and follow-up KA and VHL correction levels between the groups. A p-value of less than 0.005 was considered to indicate a statistically significant result.

RESULTS

A total of 63 patients underwent balloon kyphoplasty between September 2014 and October 2016. Nine patients had 2; one patient had 3 simultaneous VCFs, resulting in a total of 74 procedures.

Postoperative KA and VHL improved from 15.3 ± 11.4 degrees and 53.6 ± 13.4 % to 8.02 ± 2.9 degrees and 74.7 ± 11.3 % respectively (p<0.05). These values slightly deteriorated at the final follow-up, but it was not significant. The improvement was still significant at the final follow-up (p<0.05). The restoration of the vertebral height was 21.1 %. There were also immediate clinical improvement postoperatively; the VAS and ODI scores were improved from 8.1 ± 0.8 and 66.5 ± 7.1 to 2.2 ± 1.4 and 26.7 ± 5.3 respectively (p<0.001). Although, this early postoperative improvement was slightly lost at the final follow-up, the improvements from the preoperative values were still significant (VAS: 2.7 ± 1.6; ODI: 27.1 ± 4.1. p<0.001) (Table-2).

Mean bone cement (PMMA) volume was 4.6 ± 1.3 ml. There were cement leakage in 5 procedures (6.7 %) and all of them were to the disc space, and 11 (14.8 %) adjacent segment fractures (ASF) were detected during the follow-up. ASF was above the fractured vertebra in 7 cases (63.6 %), it was below the fractured vertebra in 3 cases (27.3 %), and there were one ASF (9 %) between the two fractured vertebrae.

There was more than 5 % decrease in the mean vertebral height between the measurements taken before the procedure and at the final follow up with accompanying osteolysis in 9 (12.2 %) cases. There was no accompanying history of trauma. These were recognized as recollapses. There were no cases of cardiopulmonary adverse events associated with cement leakage and no neurological symptoms were observed.

Table-2. Clinical and radiological outcomes. KA: Kyphosis angle, in degrees, VHL: Vertebral height loss, VAS: Visual analog scale for pain, ODI: Oswestry disability index. * preoperative – postoperative value significance $p < 0.001$, † preoperative – final follow-up value significance $p < 0.001$).

	Preop	Postop	Final Follow-up
KA (Degrees)	15.3 ± 11.4	$8.02 \pm 2.9^*$	$9.83 \pm 2.7^\dagger$
VHL (%)	53.6 ± 13.4	$74.7 \pm 11.3^*$	$71.3 \pm 11.7^\dagger$
VAS	8.1 ± 0.8	$2.2 \pm 1.4^*$	$2.7 \pm 1.6^\dagger$
ODI	66.5 ± 7.1	$26.7 \pm 5.3^*$	$27.1 \pm 4.1^\dagger$

DISCUSSION

Primary goals of symptomatic vertebral compression fractures are pain relief, restoration of the vertebral height, restoring sagittal profile, early mobilization and thus improving general well-being of the patient. Balloon kyphoplasty is minimally invasive, effective and relatively safe procedure for achieving these goals when conservative treatment fails.

It has been reported that effective reduction of kyphotic wedge through balloon kyphoplasty is possible (7,20-21,33).

The initial VHL was 53.6 ± 13.4 % before the balloon kyphoplasty in our series; we successfully corrected the vertebral height by 21.1% to 74.7 ± 11.3 % ($p < 0.005$). The local kyphosis angle was 15.3 ± 11.4 degrees and it was improved to 8.02 ± 2.9 degrees postoperatively ($p < 0.005$). VHL restoration by balloon kyphoplasty was reported to be between 12.8 – 31.7 % (1,28,33). The correction in the kyphosis angle was reported between 3.9 - 16.5 degrees (1,27-28,33,35). The lowest correction was reported in a group of patients with rheumatoid arthritis (28).

Although there were several authors indicating minor deterioration of postoperative VAS and ODI scores, significant improvement persists over the follow up period as we had seen in our group (VAS: 2.7 ± 1.6 ; ODI: 27.1 ± 4.1 ; $p < 0.001$) (17,28).

PMMA stabilizes fractured fragments and reduces pain, and it keeps the fractured vertebra in corrected position. The immediate pain relief effect of balloon kyphoplasty and functional recovery were well established (1,10-11,18,28,33,36). Although, there were several studies showing

diminishing pain relief and functional recovery throughout a follow up period of 12 months, they all indicated that the improvement from the preoperative state was still significant (3,17,28,34). Our results revealed significant pain relief and improvement of function in early postoperative period. Although this improvement diminished slightly at the final follow up, it was not significant. The significant improvement from the preoperative period was still maintained.

The volume of the cement (PMMA) to be injected had not been strictly defined, 2 – 6 ml of PMMA was usually suggested to repair a fractured vertebral body and up to 8 ml of PMMA was showed to remodel vertebral stiffness (14,20,23). However, no correlation could be shown between greater cement volume and pain relief (9,18).

It was pointed out that higher bone cement volumes were accompanied with higher risk of leakage and increased stresses in the adjacent vertebral bodies, in particular in the cranial vertebral body (2,15,31). The cement leak was reported in a wide range between 4 – 45 % (1,9,27,28). The average cement volume given in the 45 % leak was relatively high (6.4 ± 1.8 ml) and all the patients had rheumatoid arthritis. Our average cement volume was 4.6 ± 1.3 ml, and we had relatively low rate of cement leak, only in 5 patients (6.7 %). We observed 11 (14.8 %) ASF, 7 (63.6 %) of them were in the cranial vertebra. ASF was reported to be between 9.6 – 21.7 %, and majority of the fractures were in the cranial segment (9,28–30,32).

Recollapse of the operated vertebra was reported to be between 12.5 – 22.5 % (17,28). This recollapse was attributed to stress shielding effect of PMMA, and/or osteonecrosis induced by PMMA by some authors (10,16). It was reported to be seen

higher in kyphoplasty patients rather than vertebroplasty. Interdigitation of PMMA with cancellous bone was proposed to prevent stress shielding. It was proposed that cyst like defect caused by osteonecrosis formed solid volume of PMMA in the vertebral body, and load transfer occurred through this lump of PMMA rather than interdigitated PMMA (10). We detected similar recollapse rate (12.2 %) in our patients.

Balloon kyphoplasty is an effective and safe procedure that can provide early pain relief, improve function and correct the deformity in spontaneous osteoporotic vertebral body fractures. Although complications such as cement leakage causing neurologic compromise or pulmonary embolus are low, fractures in the adjacent segments of recollapses in the fractured vertebra can be seen.

REFERENCES

1. Ateş A, Gemalmaz HC, Deveci MA, Şimşek SA, Çetin E, Şenköylü A. Comparison of effectiveness of kyphoplasty and vertebroplasty in patients with osteoporotic vertebra fractures. *Acta Orthop Traumatol Turc* 2016; 2–5.
2. Boger A, Heini P, Windolf M, Schneider E. Adjacent vertebral failure after vertebroplasty: A biomechanical study of low-modulus PMMA cement. *Eur Spine J* 2007; 16(12): 2118–2125.
3. Coumans J V, Reinhardt MK, Lieberman IH. Kyphoplasty for vertebral compression fractures: 1-year clinical outcomes from a prospective study. *J Neurosurg* 2003; 99(Suppl.-1): 44–50.
4. Fairbank JC, Couper J, Davies JB OJ. The Oswestry low back pain disability questionnaire. *Physiotherapy* 1980; 66(8): 271–273.
5. Garfin SR, Reilley MA. Minimally invasive treatment of osteoporotic vertebral body compression fractures. *Spine J* 2002; 2(1): 76–80.
6. Garfin SR, Yuan HA, Reiley MA. New technologies in spine: kyphoplasty and vertebroplasty for the treatment of painful osteoporotic compression fractures. *Spine* 2001; 26(14): 1511–1515.
7. Grohs JG, Matzner M, Trieb K, Krepler P. Minimal invasive stabilization of osteoporotic vertebral fractures: a prospective nonrandomized comparison of vertebroplasty and balloon kyphoplasty. *J Spinal Disord Tech* 2005; 18(3): 238–242.
8. Heaney RP. The natural history of vertebral osteoporosis. Is low bone mass an epiphenomenon? *Bone* 1992; 13(Suppl.-2): S23–26.
9. He X, Li H, Meng Y, Huang Y, Hao DJ, Wu Q LJ. Percutaneous Kyphoplasty Evaluated by Cement Volume and Distribution: An Analysis of Clinical Data. *Pain Physician* 2016; 19(7): 495–506.
10. Heo DH, Chin DK, Yoon YS, Kuh SU. Recollapse of previous vertebral compression fracture after percutaneous vertebroplasty. *Osteoporos Int* 2009; 20(3): 473–480.
11. Hirakawa M, Kobayashi N, Ishiyama M, Fuwa S, Saida Y, Honda H, Numaguchi Y. Radiological findings as favorable predictors of pain relief in patients with osteoporotic compression fractures after percutaneous vertebroplasty: A retrospective study of 156 cases. *Jpn J Radiol* 2012; 30(5): 407–414.
12. Hulme PA, Krebs J, Ferguson SJ, Berlemann U. Vertebroplasty and kyphoplasty: A systematic review of 69 clinical studies. *Spine* 2006; 31(17): 1983–2001.
13. Jalava T, Sarna S, Pylkkänen L, Mawer B, Kanis J a, Selby P, Davies M, Adams J, Francis RM, Robinson J, et al. Association between vertebral fracture and increased mortality in osteoporotic patients. *J Bone Miner Res* 2003; 18(7): 1254–1260.
14. Kim DJ, Kim TW, Park KH, Chi MP, Kim JO. The proper volume and distribution of cement augmentation on percutaneous vertebroplasty. *J Korean Neurosurg Soc* 2010; 48(2): 125–128.
15. Kim JM, Shin DA, Byun DH, Kim HS, Kim S, Kim HI. Effect of bone cement volume and stiffness on occurrences of adjacent vertebral fractures after vertebroplasty. *J Korean Neurosurg Soc* 2012; 52(5): 435–440.
16. Kim MJ, Lindsey DP, Hannibal M, Alamin TF. Vertebroplasty versus kyphoplasty: biomechanical behavior under repetitive loading conditions. *Spine* 2006; 31(18): 2079–2084.
17. Kim YY, Rhyu KW. Recompression of vertebral body after balloon kyphoplasty for osteoporotic vertebral compression fracture. *Eur Spine J* 2010; 19(11): 1907–1912.
18. Komemushi a, Tanigawa N, Kariya S, Kojima H, Shomura Y, Sawada S. Percutaneous vertebroplasty for compression fracture: analysis of vertebral body volume by CT volumetry. *Acta Radiol* 2005; 46: 276–279.
19. Ledlie JT, Renfro MB. Kyphoplasty treatment of vertebral fractures: 2-year outcomes show sustained benefits. *Spine* 2006; 31(1): 57–64.
20. Liebschner MA, Rosenberg WS, Keaveny TM. Effects of bone cement volume and distribution on vertebral stiffness after vertebroplasty. *Spine* 2001; 26(14): 1547–1554.

-
21. Liu JT, Liao WJ, Tan WC, Lee JK, Liu CH, Chen YH, Lin TB. Balloon kyphoplasty versus vertebroplasty for treatment of osteoporotic vertebral compression fracture: a prospective, comparative, and randomized clinical study. 2010; 21(2): 359–364.
 22. Lovi A, Teli M, Ortolina A, Costa F, Fornari M, Brayda-Bruno M. Vertebroplasty and kyphoplasty: Complementary techniques for the treatment of painful osteoporotic vertebral compression fractures. A prospective non-randomised study on 154 patients. *Osteoporos Int* 2009; 18(Suppl.-1): 95-101.
 23. Molloy S, Mathis JM, Belkoff SM. The effect of vertebral body percentage fill on mechanical behavior during percutaneous vertebroplasty. *Spine* 2003; 28(14): 1549–1554.
 24. Movrin I, Vengust R, Komadina R. Adjacent vertebral fractures after percutaneous vertebral augmentation of osteoporotic vertebral compression fracture: A comparison of balloon kyphoplasty and vertebroplasty. *Arch Orthop Trauma Surg* 2010; 130(9): 1157–1166.
 25. Rapado A. General management of vertebral fractures. *Bone* 1996; 18(Suppl.-3): 191S–196S.
 26. Reginster J, Minne HW, Sorensen OH, Hooper M, Roux C, Brandi ML, Lund B, Ethgen D, Pack S, Roumagnac I, Eastell R. Randomized trial of the effects of risedronate on vertebral fractures in women with established postmenopausal osteoporosis. Vertebral Efficacy with Risedronate Therapy (VERT) Study Group. *Osteoporos Int* 2000; 11(1): 83–91.
 27. Robinson Y, Heyde CE, Försth P, Olerud C. Kyphoplasty in osteoporotic vertebral compression fractures--guidelines and technical considerations. *J Orthop Surg Res* 2011; 6: 43.
 28. Shim J, Lee K, Kim H, Kang B, Jeong H, Kang C-N. Outcome of balloon kyphoplasty for the treatment of osteoporotic vertebral compression fracture in patients with rheumatoid arthritis. *BMC Musculoskelet Disord* 2016; 17(1): 365.
 29. Syed MI, Patel NA, Jan S, Harron MS, Morar K, Shaikh A. New symptomatic vertebral compression fractures within a year following vertebroplasty in osteoporotic women. *AJNR Am J Neuroradiol* 2005; 26(6): 1601–1604.
 30. Taylor RS, Fritzell P, Taylor RJ. Balloon kyphoplasty in the management of vertebral compression fractures: an updated systematic review and meta-analysis. *Eur Spine J* 2007; 16(8): 1085–1100.
 31. Trout AT, Kallmes DF. Does vertebroplasty cause incident vertebral fractures? A review of available data. *AJNR Am J Neuroradiol* 2006; 27(7): 1397–1403.
 32. Uppin A a, Hirsch J a, Centenera L V, Pfeifer B a, Pazianos AG, Choi IS. Occurrence of new vertebral body fracture after percutaneous vertebroplasty in patients with osteoporosis. *Radiology* 2003; 226: 119–124.
 33. Voggenreiter G, Brocker K, Rohrl B, Sadick M, Obertacke U. [Results of balloon kyphoplasty in the treatment of osteoporotic vertebral compression fractures]. *Unfallchirurg* 2008; 111(6): 403–412.
 34. Wardlaw D, Cummings SR, Van Meirhaeghe J, Bastian L, Tillman JB, Ranstam J, Eastell R, Shabe P, Talmadge K, Boonen S. Efficacy and safety of balloon kyphoplasty compared with non-surgical care for vertebral compression fracture (FREE): a randomised controlled trial. *Lancet* 2009; 373(9668): 1016–1024.
 35. Yaltirik K, Ashour AM, Reis CR, Özdoğan S, Atalay B. Vertebral augmentation by kyphoplasty and vertebroplasty: 8 years experiences outcomes and complications. *J Craniovertebr Junction Spine* 2016; 7(3): 153–160.
 36. Yu CW, Hsieh MK, Chen LH, Niu CC, Fu TS, Lai PL, Chen WJ, Chen WC, Lu ML. Percutaneous balloon kyphoplasty for the treatment of vertebral compression fractures. *BMC Surg* 2014; 14: 14-23.