



ANATOMY OF THE UPPER SACRAL AND THE SECOND SACRAL NERVE ROOT TUNNELS: A MORPHOLOGIC STUDY

ÜST SAKRAL VE İKİNCİ SAKRAL KÖK TÜNELLERİNİN ANATOMİSİ: MORFOLOJİK ÇALIŞMA

Emre KARADENİZ¹,
Sedat DUMAN¹

¹ Surgeon of Orthopaedics and Traumatology, Umraniye Education and Training Hospital, Istanbul, Turkey

SUMMARY:

Sacral anatomy is unique when compared to the other vertebral columns. The posterior structure of the sacrum is similar to the upper part of the spinal column but the fusion between these segments.

On the other hand, anterior anatomy of the sacrum contains a bony bridge between the transverse processes and the vertebral body. This bony bridge contains tunnels. Anterior foramen of the S1 and S2 nerve root leaves the spinal canal in this bony tunnel and reaches to abdominal cavity. In this study we define the coronal angle of these two S1 and S2 tunnels on CT scans of 76 patients.

Key words: Sacrum; anatomy; posterior pelvis; sacral nerve root

Level of Evidence: Retrospective clinical study, Level III

ÖZET:

Sakrum anatomisi, diğer vertebral kolon ile kıyaslandığında benzersizdir. Genel olarak, sakrum posterior kemik yapıları, üst vertebral kolon anatomisi ile büyük benzerlik göstermektedir ancak aradaki tek fark bu anatomik yapılar arasındaki füzyondur.

Ancak; sakrumun anterior anatomisi vertebra korpuslarının sadece füzyonundan ibaret değildir. Anterior sakrumda vertebra gövdeleri arasında füzyona ek olarak vertebra korpusundan transvers çıkıntılara uzanan bir kemik blok vardır. Bu kemik bloğun içinden ilgili sinir kökünün anterior ramusu; adeta bir kemik tünel içerisinden anterior foramen aracılığı ile abdominal kaviteye açılmaktadır. Bu anatomiyi anlamının ameliyat esnasında cerrahlara büyük kolaylık sağlayacağı muhakkaktır. Bu çalışmanın amacı: S1 ve S2 anterior ramuslarının geçtiği kemik tünellerin anatomisini tanımlamaktır. Bu amaçla 76 hastanın pelvis bilgisayarlı tomografileri değerlendirilmiş ve bu tünellerin koronal planda yaptıkları açılanmalar ölçülmüştür.

Anahtar Kelimeler: Sakrum; anatomi; posterior pelvis; sacral sinir kökleri

Kanıt Düzeyi: Retrospektif klinik çalışma, Düzey IV

Corresponding Author:

Dr. Emre KARADENİZ
Address: Site Mah. Cevahir Cad.
Soyak Selale Evleri D-3 Blok, Daire:4
Umraniye, Istanbul, Turkey
e-Mail: ekaradenizmd@yahoo.com
Phone: +90 532 2816850
Received: 12th April, 2016.
Accepted: 20th June, 2016.

INTRODUCTION:

Anatomy of the sacrum is complex. In addition to the unusual bony architecture, many vital structures are located within millimeters of the safe bony corridor for implant placement^{3,14}. Anterior foramen of the S1 nerve root (containing the anterior ramus) leaves the spinal canal in a bony tunnel and reaches to abdominal cavity. In the literature this tunnel is named as “upper sacral nerve root tunnel (USNRT)” by Farrell ED et al.⁵. In that article the course of the USNRT tunnel has been defined and studied by trauma surgeons for iliosacral screw placement. Farrell et al. defined the USNRT tunnel course on pelvic outlet views.

For pedicle screw or alar screw placement the course of this tunnel is also important. And during prone positioned spinal surgery, outlet view of the sacrum is not easy to achieve and hard to cooperate.

In the literature, there is no data for the course of USNRT on coronal plane during the prone positioned spinal surgery. The aim of this study is to anatomically define the coronal angle of USNRT from CT images.

The definition of the USNRT by trauma surgeons is only for S1 sacral nerve root. But for spinal surgery and sacral fracture surgery, additionally we need to define the S2 nerve root tunnel (S2NRT). To our knowledge; in the literature there is no definition for the S2NRT anatomy and this study defines the coronal course of this S2NRT.

MATERIALS AND METHODS:

Patients who had a pelvic CT in our hospital were retrospectively defined. The exclusion criteria's for the study group was; having anomaly or fracture of the sacrum, pelvis or lumbar vertebral column.

Seventy six patients with pelvis CT selected for the study group. On these CT scans the coronal slices were detected for the USNRT and S2NRT measurements.

For USNRT coronal angle measurements; a midline was defined from the S1 vertebral corpus. Then a second line drawn from the midpoint of the proximal and distal part of the USNRT. The angles between these lines were calculated bilaterally (**Figure-1**).

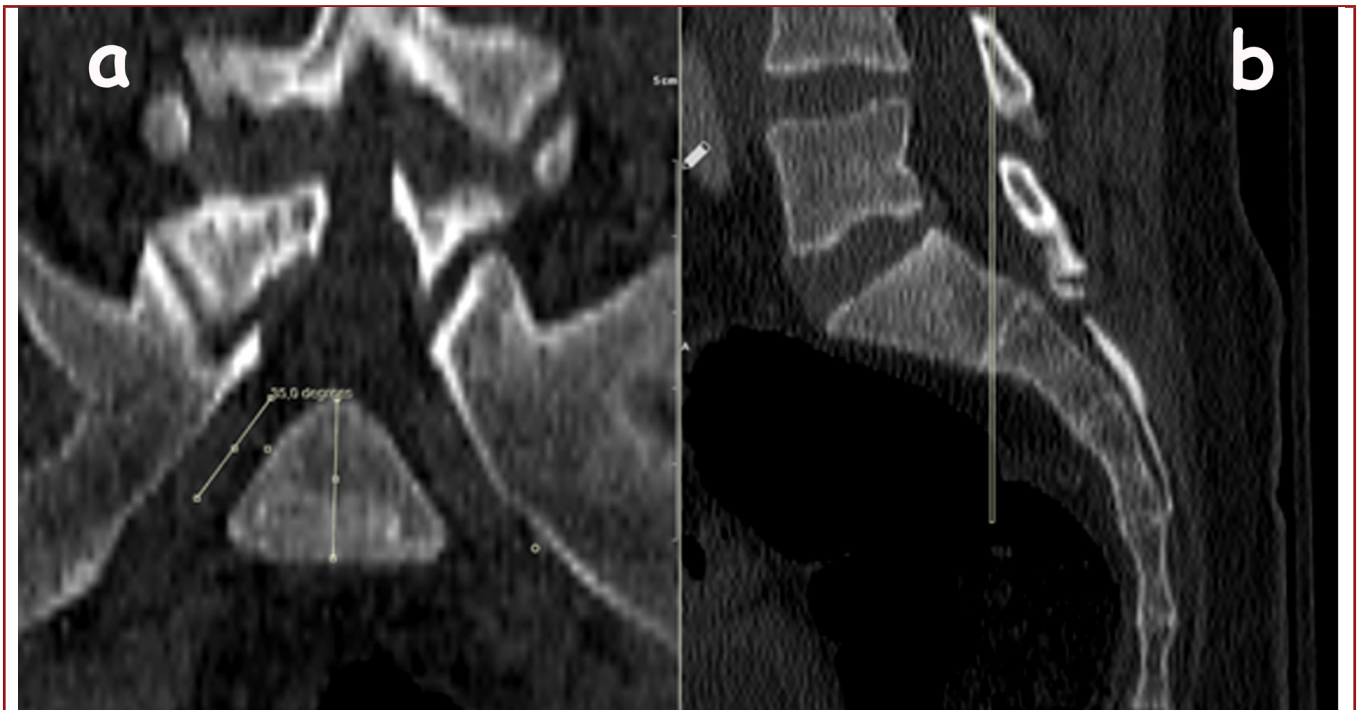


Figure-1. CT of the pelvis **a)** The coronal view of the USNRT. The tunnel course angle from the midline measured between vertebral corpus vertical line and the USNRT line. **b)** The sagittal CT section, showing the coronal view orientation which was used to measure the USNRT course angle.

For S2NRT coronal angle measurements; a midline was defined from S2 vertebral corpus. Then the second line defined from the midpoint of the proximal and distal of the S2NRT.

The angles between these two lines were measured bilaterally (**Figure-2**).

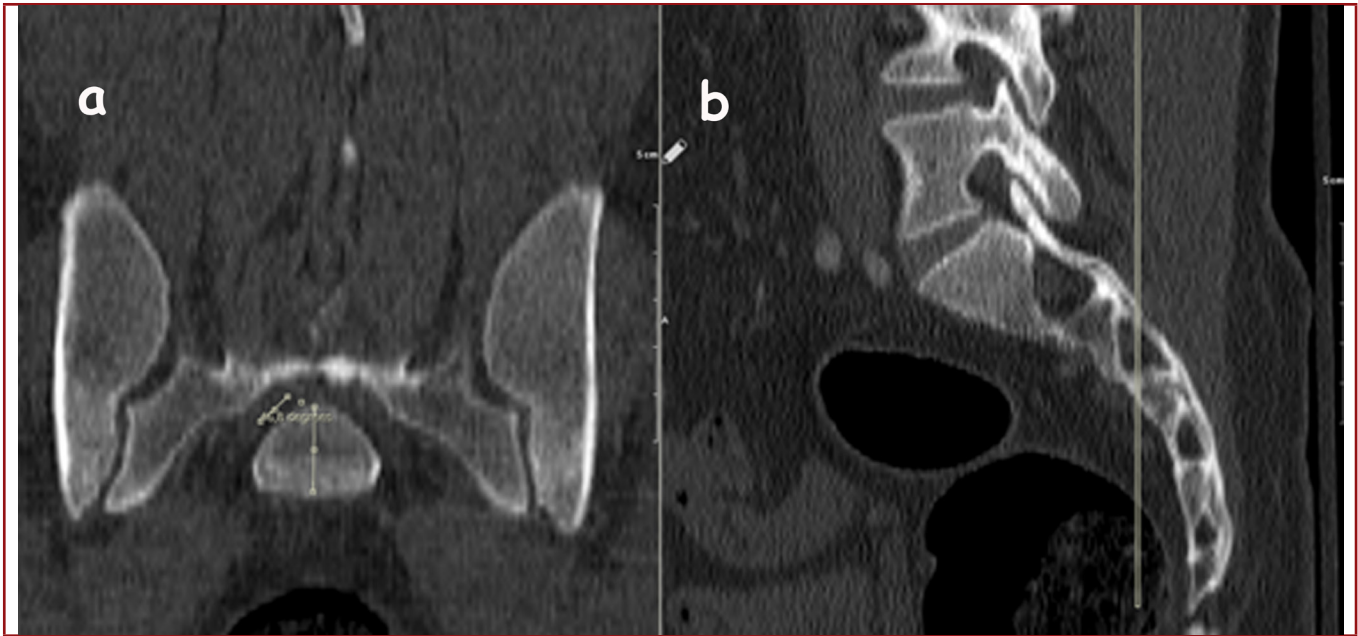


Figure-2. CT of the pelvis **a)** The coronal view of the S2NRT. The tunnel course angle from the midline measured between vertebral corpus vertical line and the S2NRT line. **b)** The sagittal CT section, showing the coronal view orientation which was used to measure the S2NRT course angle.

RESULTS:

The average age was 47 years (range, 5-85) and there were 31 male and 45 female patients.

The mean right side upper sacral nerve root tunnel (USNRT) coronal angle was 32° (range, 24°-45°) and mean left side USNRT angle was 32° (range, 18°-50°). The mean right side S2NRT coronal angle was 39° and the mean left side S2NRT angle was 39° (range, 21°-55°) (**Table-1**).

The mean right side USNRT coronal angle in male group was 32° (range, 24°-39°) and in the female group the mean right

USNRT angle was 32° (range, 26°-45°). The left side USNRT angle in the male group was 31° (range, 23°-50°) and in the female group the mean left USNRT angle was 33° (range 18°-43°) (**Table-1**).

The mean right side S2NRT coronal angle in male group was 37° (range, 27°-52°) and in the female group the mean right S2NRT angle was 40° (range, 26°-49°). The left side S2NRT angle in the male group was 37° (range, 21°-55°) and in the female group the mean left S2NRT angle was 41° (range 22°-54°) (**Table-1**).

Table-1. Measured coronal angles of upper sacral nerve root tunnel (USNRT) and the S2 nerve root tunnel (S2NRT).

	USNRT		S2NRT	
	Right	Left	Right	Left
Male	32° (range, 24°-39°)	31° (range, 23°-50°)	37° (range, 27°-52°)	37° (range, 21°-55°)
Female	32° (range, 26°-45°)	33° (range, 18°-43°)	40° (range, 26°-49°)	41° (range 22°-54°)
Mean	32° (range, 24°-45°)	32° (range, 18°-50°)	39° (range, 26°-52°)	39° (range, 21°-55°)

DISCUSSION:

Numerous authors have investigated the conditions of the posterior pelvis based on Xray images or CT scans^{1-2,6,11-13,15}. In the literature; for iliosacral screw placement, USNRT and the angle of their course have been defined from outlet view of the sacrum. Ziran et al. define the osseous anatomy of the USNRTs as complex and is oblique in all 3 cardinal planes beginning within the midline sacral spinal canal. The tunnels then course laterally (approximately 60 degrees from the midline on the outlet view), anteriorly (approximately 20 degrees from the midline on the inlet view), and inferiorly on the lateral view¹⁷.

Jackson et al. defined the USNRT exit point of the upper sacral neural foramen, which is a trumpet-shaped orifice in the anterior sacrum where the nerve root exits⁷.

The radiographic image of the USNRT is best seen on the pelvic outlet image, and screw placement above the upper sacral neural foramen on this view is critical.⁹ However, additional anatomic information is necessary and available on the outlet and other views that guide intraosseous screw placement¹⁶. Also, on the outlet view, the radiolucent spica cast appearance of the USNRT can and should be identified, and this is often a good starting point for visualizing the three dimensional structure of the nerve root tunnels. It is important to recognize that the more readily visualized foramina are only the exit points of the obliquely oriented tunnels. The two tunnels or spica cast thighs are formed by the radiodense medial and lateral corticated tunnel walls and the relative radiolucency of the interposed tunnel containing the nerve root. Ideally, an extreme outlet view would be used to position the fluoroscopic beam along the same axis as the USNRT to ensure that the screw is positioned anteriorly, but the sagittal plane obliquity is approximately 60 degrees, and it is rarely feasible to obtain this degree of outlet tilt in a surgical situation¹⁷. Although USNRT visualization on a standard outlet view is not as apparent as the upper sacral neural foramen, the USNRT spica cast was seen in all patients in this consecutive clinical series.

During posterior instrumentation; to be successful and safe, a thorough understanding of the complex bony and posterior pelvic fluoroscopic architecture is critical. In particular, the surgeon must have a clear sense of the spinal canal, the sacral ala, the vertebral cortical limits, and particularly the USNRT position and course^{4,8,10}.

During sacral surgery with posterior approach, because of the fusion mass between the vertebra corpus and the posterior anatomic structures, the only reference point for the surgeon is the posterior foramens⁴. And the anterior foramens are not in the same horizontal plane of the posterior foramens due to sacral slope. In prone positioned patient, defining the USNRT course from outlet and inlet view of the pelvis is hard to achieve and cooperate. Because of poor anatomic landmarks,

poor visualization and complex anatomy of the sacrum, spinal surgeon needs well defined USNRT course¹⁰.

In our study, on coronal plane the mean USNRT angle from midline was 32 degrees (18° to 50°). This acute angle means a safe bony corridor just inferior and superior to the posterior foramens of the sacrum. With additional anatomic and morphologic studies, the definition of this bony corridor may cause new posterior S1 screw placement techniques.

In the literature the S2NRT course has never been defined. We think that; definition of S2NRT is critical for S2 posterior screw placement during posterior instrumentation of the spine or sacral fracture fixation. In our study the course of S2NRT course angle from the midline was 39 degrees. As in USNRT this acute angle of the S2NRT means a bone corridor to the S2 vertebrae corpus. With additional study to definition of this bony corridor; a screw placement technique which does not need to be lateral to the posterior foramens of the sacrum may be defined.

As a conclusion; for sacral screw placement with posterior approach, the definition of the USNRT and S2NRT course is critical. Surgeon must have a clear sense of these anatomic structures. We have demonstrated the USNRT and S2NRT location on coronal plane which means, a bony corridor just superior and inferior of the posterior foramens of the sacrum. We believe that with additional study, there would be a definition of a new posterior screw placement technique for the sacrum.

REFERENCES:

1. Carlson GD, Abitbol JJ, Anderson DR, Krag MH, Kostuik JP, Woo SL, Garfin SR. Screw fixation in the human sacrum. An in vitro study of the biomechanics of fixation. *Spine* 1992; 17: S196–203.
2. Day CS, Prayson MJ, Shuler TE, Towers J, Gruen GS. Transsacral versus modified pelvic landmarks for percutaneous iliosacral screw placement – a computed tomographic analysis and cadaveric study. *Am J Orthop* 2000; 29: 16–21.
3. Ebraheim NA, Lu J, Biyani A. Location of the first and second sacral nerve roots in relation to pedicle screw placement. *Am J Orthop* 2000; 29: 873–877.
4. Esses SI, Botsford DJ, Huler RJ, Rauschnig W. Surgical anatomy of the sacrum. A guide for rational screw fixation. *Spine* 1991; 16(6 Suppl): S283–288.
5. Farrell ED, Gardner MJ, Krieg JC, Chip Routh ML Jr. The upper sacral nerve root tunnel: an anatomic and clinical study. *J Orthop Trauma* 2009; 23(5): 333–339.

-
6. Hasenboehler EA, Stahel PF, Williams A, Smith WR, Newman JT, Symonds DL, Morgan SJ. Prevalence of sacral dysmorphism in a prospective trauma population: implications for a safe surgical corridor for sacro-iliac screw placement. *Patient Saf Surg* 2011; 5: 8.
 7. Jackson H, Burke JT. The sacral foramina. *Skeletal Radiol* 1984; 11: 282–288.
 8. Licht NJ, Rowe DE, Ross LM. Pitfalls of pedicle screw fixation in the sacrum. A cadaver model. *Spine* 1992; 17(8): 892–896.
 9. Mendel T, Noser H, Kuervers J, Goehre F, Hofmann GO, Radetzki F. The influence of sacral morphology on the existence of secure S1 and S2 transverse bone corridors for iliosacroiliac screw fixation. *Injury* 2013; 44(12): 1773–1779.
 10. Mirkovic S, Abitbol JJ, Steinman J, Edwards CC, Schaffler M, Massie J, Garfin SR. Anatomic consideration for sacral screw placement. *Spine* 1991; 16(6 Suppl): S289–294.
 11. Noojin FK, Malkani AL, Haikal L, Lundquist C, Voor MJ. Cross-sectional geometry of the sacral ala for safe insertion of iliosacral lag screws: a computed tomography model. *J Orthop Trauma* 2000; 14: 31–35.
 12. Reilly MC, Bono CM, Litkouhi B, Sirkin M, Behrens FF. The effect of sacral fracture malreduction on the safe placement of iliosacral screws. *J Orthop Trauma* 2003; 17: 88–94.
 13. Routt Jr ML, Simonian PT, Agnew SG, Mann FA. Radiographic recognition of the sacral alar slope for optimal placement of iliosacral screws: a cadaveric and clinical study. *J Orthop Trauma* 1996; 10: 171–177.
 14. Templeman D, Schmidt A, Freese J, Weisman I. Proximity of iliosacral screws to neurovascular structures after internal fixation. *Clin Orthop Relat Res* 1996; 329: 194–198.
 15. Tonetti J, Cloppet O, Clerc M, Pittet L, Troccaz J, Merloz P, Chirossel J. Implantation of iliosacral screws. Simulation of optimal placement by 3-dimensional X-ray computed tomography. *Rev Chir Orthop Reparatrice Appar Mot* 2000; 86: 360–369.
 16. Xu R, Ebraheim NA, Robke J, Huntoon M, Yeasting RA. Radiologic and anatomic evaluation of the anterior sacral foramina and nerve grooves. *Spine* 1996; 21: 407–410.
 17. Ziran BH, Wasan AD, Marks DM, Olson SA, Chapman MW. Fluoroscopic imaging guides of the posterior pelvis pertaining to iliosacral screw placement. *J Trauma* 2007; 62: 347–356.

