



## NEUROLOGIC DEFICIT SECONDARY TO CEMENT LEAKAGE DURING PERCUTANEOUS VERTEBROPLASTY IN MULTIPLE MYELOMA PATIENT

### MULTİPL MYELOMALI HASTADA PERKÜTAN VERTEBRAPLASTİ SONRASI SEMENT KAÇAĞINA BAĞLI GELİŞEN NÖROLOJİK DEFİSİT

Murat MERT<sup>1</sup>,  
Sinan ERDOĞAN<sup>2</sup>,  
Bahadır GÖKÇEN<sup>2</sup>,  
Selahattin ÖZYÜREK<sup>3</sup>,  
Çağatay ÖZTÜRK<sup>2</sup>

<sup>1</sup>Department of Orthopaedics and Traumatology, Gaziosmanpaşa Private Hospital, Gaziosmanpaşa, İSTANBUL

<sup>2</sup>Liv Hospital, Liv Spine Center, Ulus, İSTANBUL

<sup>3</sup>Department of Orthopaedics and Traumatology, Turkish Naval Academy Family Health Center, İSTANBUL

#### SUMMARY:

Percutaneous vertebroplasty is defined as the injection of polymethylmethacrylate into the vertebral body under general or local anesthesia with radiological guidance to provide pain relief and structural support. Vertebroplasty was first used in the treatment of vertebral angiomas. However the most common indication of percutaneous vertebroplasty is the osteoporotic fractures of the spine resistant to conservative treatment. Although percutaneous vertebroplasty is a minimally invasive procedure, it has limited complications. Cement leakage is frequent complication of the procedure. In this study, we report a possible complication of the percutaneous vertebroplasty procedure. We aim to emphasize that we should be careful about the treatment of vertebral fractures with percutaneous vertebroplasty for neurological complications.

**Key Words:** vertebroplasty, complication, cement leakage

**Level of evidence:** Case report, Level IV

#### ÖZET:

Perkütan vertebroplasti, spinal kolonun osteoporoz, travmaya ve maligniteye bağlı kompresyon kırıklarında uygulanan bir tedavi yöntemidir. Floroskopi eşliğinde kanül yardımıyla polimetilmetakrilatın (PMMA) etkilenmiş vertebra korpusu içerisine enjekte edilmesi işlemidir. Perkütan vertebroplasti; genel olarak iyi tolere edilebilen, sınırlı komplikasyonu olan bir teknik olmakla birlikte sement kaçağı sık görülen komplikasyondur. Sement kaçağı nadiren nörolojik defisit, akciğer veya diğer organ sistemlerinde emboliye neden olmaktadır. Perkütan vertebroplastinin major komplikasyonlara açık olabileceği akılda tutulmalıdır. Spinal kaçak sonrası oluşan nörolojik defisitlerde erken dönemde sementin çıkartılmasının klinik iyileşme üzerine olumlu etkileri olduğunu düşünmekteyiz.

**Anahtar Kelimeler:** Vertebroplasti, komplikasyon, sement kaçağı

**Kanıt Düzeyi:** Olgu sunumu, Düzey IV

**Address:** Murat MERT,  
Özel Gaziosmanpaşa Hastanesi  
Merkez Mah. Çukurçeşme Caddesi,  
No:51 Gaziosmanpaşa / İSTANBUL  
**Gsm:** 0532 323 28 58  
**E-mail:** sinanerdogan@hotmail.com  
**Received:** 1st August, 2015  
**Accepted:** 22th September, 2015

## INTRODUCTION:

Percutaneous vertebroplasty was first performed clinically on vertebral hemangioma in 1980. As lifespan is getting longer and life quality expectancy is increasing with the developing technology and growing experience, practice of percutaneous vertebroplasty has been increasing<sup>10</sup>.

Percutaneous vertebroplasty is a minimally invasive technique, in which acrylic cement is used and it is performed on compression fractures related to osteoporosis, trauma and malignancy<sup>7,11,14</sup>. In vertebral compression fractures, percutaneous vertebroplasty is recommended for the fractures which do not respond to a six weeks conservative treatment and for the ones which occur between T5-L5 vertebrae corpuses with posterior body walls are healthy<sup>7,9,11,17</sup>. In this surgical technique, polymethylmethacrylate injection (PMMA) is done by inserting into the affected vertebra corpus with cannulas in company with fluoroscopic x-ray guidance.

In this case report, we aim to emphasize that we should be careful about the treatment of vertebral fractures with percutaneous vertebroplasty for neurological complications.

## CASE REPORT:

Multiple myeloma pre-diagnosis of a 72 year old male patient who had backache and low back pain following an incident of falling down and had a six week conservative treatment with brace and NSAII as a result of compression fractures on T7-8-9-11 and L1 vertebrae. A single level vertebroplasty had been performed on the patient because of an isolated T6 compression fracture in another hospital one year ago. The

pain complaints of the patient and local sensitiveness in the examination were matching to the fracture area. Both of the neurovascular examinations on lower extremities were normal. Subacute fractures related to multiple myeloma were seen in magnetic resonance imaging and it was also confirmed with laboratory examinations. Vertebra corpus posterior wall was evaluated intact in computed tomography. Percutaneous vertebroplasty was decided to be done owing to the prolonged pain of the patient in spite of conservative treatment.

Under general anesthesia, the patient was laid down in the prone position. Indirect reduction was tried to be ensured by taking to hyperextension and putting cushions on chest and pelvis in terms of fractured reduction. Accompanied by fluoroscopy, 15 gauge cannulas were placed into the vertebra corpus as a percutaneous by the anterior-posterior, lateral and oblique images. In the lateral graphs, the cannula tip was tried to be placed into the anterior of vertebra corpus or medial 1/3 part. In the process of radiopaque bone cement injection, the risk of cement leakage was tried to be decreased by constant fluoroscopy imaging. Being injected to 5 vertebra in total, 4 cc cement was injected to each vertebra by giving 2 cc to both of the pedicles.

After the surgery, total motor and sensorial neurological deficits were found in the right low extremity of the patient including the hip. In the immediate computed tomography, it was seen that there was a cement leakage in the right side and on the T9 vertebra level towards the spinal canal (Figure-1,2). The patient was taken to the surgery again urgently. Cement piece in the spinal canal was removed by doing hemilaminectomy at T9 level. It was seen that hip flexion motor strength was recessed at the rate of 2/5 after the surgery.

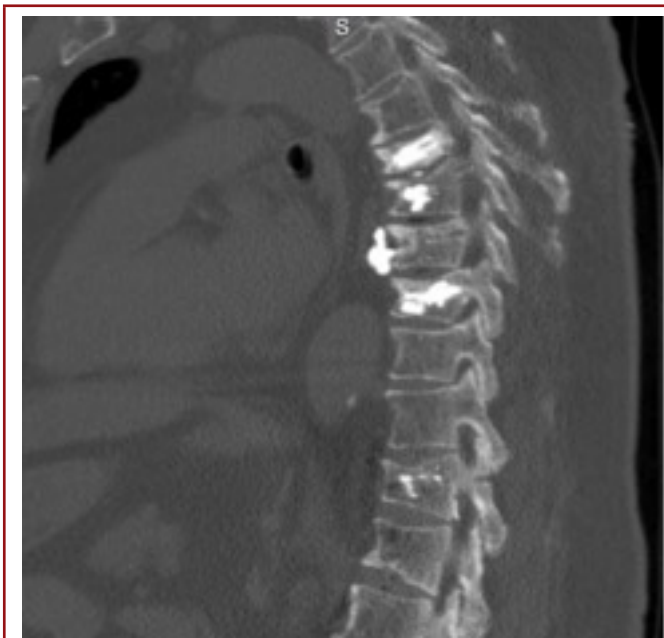


Figure 1.

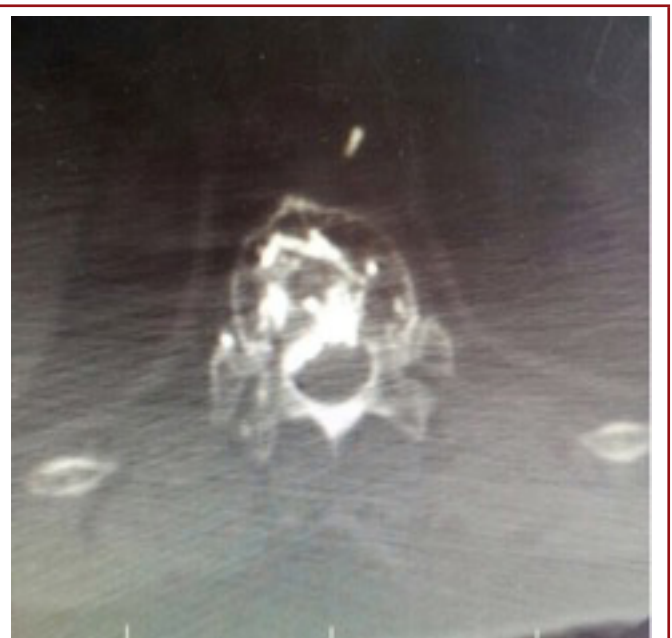


Figure 2.

## DISCUSSION:

Although percutaneous vertebroplasty is a technique which is tolerated well and has limited complications. Complications related to vertebroplasty include cement embolism, neurological deficits, discitis, and dural tears and cement leakage. Cement leakage is frequent complication of the procedure<sup>19</sup>. Cement leakage rarely causes emboly and neurological deficit in lungs and other organ systems<sup>1,8</sup>. The frequency of cement leakage in the literature was pointed out as a rate between 31 % and 96 %<sup>19</sup>. Cement leakage could be towards soft tissues in lateral, towards disc space in superior and inferior and towards spinal canal in posterior<sup>5</sup>. The cement leakage towards disc space has been reported very often and fracture in the neighbor segment<sup>6</sup>, disc herniation and radiculopathy have been reported as a consequence of this leakage<sup>20</sup>. The cement leakage towards spinal canal is observed less often. In a 4547 disease series made as a multiple central study in the literature, major neurological complication was not found and it was reported that venous embolization was the most common minor complication and leakage towards disc level was at the second frequency<sup>2</sup>. Nakano et al. have stated that the risk of cement leakage development in spinal malignancy is more than the vertebroplasty performed due to the osteoporotic fractures<sup>16</sup>.

There could be cement leakage towards spinal canal from pedicle medial wall, posterior vertebra corpus, end-plate fractures and some vertebral foramens. There could be some injuries as a result of direct pressure or thermal effect of cement on spinal cord and roots<sup>3-5,12,13,15,18,19,21</sup>. Although it has been stated for many times that cement do not stick on the dura, scraping with a micro neuron coronoid and micro Penfield dissector is suggested in order not to damage neurological system while removing the cement<sup>19</sup>. It is also suggested that cement stuck on the dura can be cleaned by high speed burr and for the intradural cement leakages, duratomy and relevant root should be scraped carefully<sup>19</sup>. In our case, cement was not stuck on the dura and it was removed without dura damage. It should be kept in mind that cement could be stuck on the dura and there might be intradural leakage.

It was noted in the literature that the procedure to remove the cement could require instrumentation. Sidhu et al. have suggested instrumentation after removing the cement for the patients especially with moderate osteoporosis if they have instable vertebral injuries and if it causes iatrogenic instability and deformity by decompression<sup>19</sup>. In our case, the cement was removed with limited hemilaminectomy and there did not occurred a need for instrumentation.

Some approaches have been suggested in order to decrease the risk of neurological deficit development. It is highly necessary to guarantee that posterior body wall is intact via imaging techniques<sup>11</sup>; to make sure that cannula does not go beyond the

medial and lateral walls of pedicle in anteroposterior graphy<sup>12</sup>; to wait till the cement comes to toothpaste texture before cement injection<sup>3</sup>; to stop cement injection when it reaches ¼ posterior part of vertebral corpus<sup>21</sup>. On the other hand, some authors suggest doing the procedure with local anesthesia in order to realize the neurological deficit early<sup>19</sup>.

Percutaneous vertebroplasty is a minimally invasive and easy applicable technique which can be used for painful vertebra compression fractures dependent on osteoporosis and malignancy. However, it should be kept in mind that there could be major complications. We believe that removing the cement in the early period of neurological deficit occurred after the spinal leakage has a positive influence on clinical recovery.

## REFERENCE:

1. Al-Nakshabandi NA. Percutaneous vertebroplasty complications. *Ann Saudi Med* 2011; 31: 294–297.
2. Anselmettia GC, Marciab S, Sabac L, Mutod M, Bonaldie G, Carpeggianif P, Marinig S, Mancaa A, Masalah S. Percutaneous vertebroplasty: Multi-centric results from EVEREST experience in large cohort of patients. *Eur J Radiology* 2012; 81: 4083–4086.
3. Boger A, Bisig A, Bohner M, Heini P, Schneider E. Variation of the mechanical properties of PMMA to suit osteoporotic cancellous bone. *J Biomater Sci Polym Ed* 2008; 19:1125–1142.
4. Chen YJ, Tan TS, Chen WH, Chen CC, Lee TS. Intradural cement leakage: a devastatingly rare complication of vertebroplasty. *Spine* 2006; 31: E379–E382.
5. Chen JK, Lee HM, Shih JT, Hung ST. Combined extraforaminal and intradiscal cement leakage following percutaneous vertebroplasty. *Spine* 2007; 32: E358–E362.
6. Chen LH, Lai PL, Chen WJ. Current status of vertebroplasty for osteoporotic compression fracture. *Chang Gung Med J* 2011; 34: 352–359.
7. Chew C, Craig L, Edwards R, Moss J, O'Dwyer PJ. Safety and efficacy of percutaneous vertebroplasty in malignancy: a systematic review. *Clin Radiol* 2011; 66: 63–72.
8. Docampo E, Ciria M, Serra-Burgés J, Blanch J, Pérez Edo L, Carbonell J. Risk factors of new fractures after vertebroplasty. *Med Clin* 2009; 133: 17–19(English Abstract).
9. Eck JC, Nachtigall D, Humphreys SC, Hodges SD. Comparison of vertebroplasty and balloon kyphoplasty for treatment of vertebral compression fractures: a meta-analysis of the literature. *Spine J* 2008; 8: 488–497.

- 
10. Galibert P, Deramond H, Rosat P, Le Gars D. Preliminary note on the treatment of vertebral angioma by percutaneous acrylic vertebroplasty. *Neurochirurgie* 1987; 33(2): 166-168.
  11. Hadjipavlou AG, Tzermiadianos MN, Katonis PG, Szpalski M. Percutaneous vertebroplasty and balloon kyphoplasty for the treatment of osteoporotic vertebral compression fractures and osteolytic tumours. *J Bone Joint Surg* 2005; 87-B: 1595-1604.
  12. Laredo JD, Hamze B. Complications of percutaneous vertebroplasty and their prevention. *Skeletal Radiol* 2004; 33: 493-505.
  13. Lee BJ, Lee SR, Yoo TY. Paraplegia as a complication of percutaneous vertebroplasty with polymethylmethacrylate: a case report. *Spine* 2002; 27: E419-E422.
  14. Lieberman I, Reinhardt MK. Vertebroplasty and kyphoplasty for osteolytic vertebral collapse. *Clin Orthop Relat Res* 2003; 415 (Supl.): S176-S186.
  15. Luo J, Daines L, Charalambous A, Adams MA, Annesley-Williams DJ, Dolan P. Vertebroplasty: only small cement volumes are required to normalize stress distributions on the vertebral bodies. *Spine* 2009; 34: 2865-2873.
  16. Makano M, Hirano N, Ishihara H, Kawaguchi Y, Matsuura K. Calcium phosphate cement leakage after percutaneous vertebroplasty for osteoporotic vertebral fractures: risk factor analysis for cement leakage. *J Neurosurg Spine* 2005; 2: 27-33.
  17. Mirovsky Y, Anekstein Y, Shalmon E, Blankstein A, Peer A. Intradiscal cement leak following percutaneous vertebroplasty. *Spine* 2006; 31(10): 1120-1124.
  18. Patel AA, Vaccaro AR, Martyak GG, Harrop JS, Albert TJ, Ludwig SC, Youssef JA, Gelb DE, Mathews HH, Chapman JR, Chung EH, Grabowski G, Kuklo TR, Hilibrand AS, Anderson DG. Neurologic deficit following percutaneous vertebral stabilization. *Spine* 2007; 32: 1728-1734.
  19. Sidhu GS, Kepler CK, Savage KE, Eachus B, Albert TJ, Vaccaro AR. Neurological deficit due to cement extravasation following a vertebral augmentation procedure. *J Neurosurg Spine* 2013; 19: 61-70.
  20. Sonmez E, Yilmaz C, Caner H. Development of lumbar disc herniation following percutaneous vertebroplasty. *Spine* 2010; 35: E93-E95.
  21. Teng MM, Cheng H, Ho DM, Chang CY. Intraspinous leakage of bone cement after vertebroplasty: a report of 3 cases. *AJNR Am J Neuroradiol* 2006; 27: 224-229.