



IMPACT OF INTERBODY FUSION IN DEGENERATIVE VERTEBRAE ON SACRAL PEDICLE SCREW SURVIVAL

DEJENERATİF OMURGA TEDAVİSİNDE İNTERBODY FÜZYONUN SAKRAL PEDİKÜL VİDASI SAĞKALIMINA ETKİSİ

Okan ÖZKUNT¹,
Turgut AKGÜL²,
Kerim SARIYILMAZ¹,
Murat KORKMAZ³,
Fatih DİKİCİ⁴,
Ufuk TALU⁵,
Cüneyt ŞAR⁵

¹Surgeon of the Orthopedics and Traumatology, Department of Orthopedics and Traumatology, Acıbadem University Atakent Hospital, İstanbul.

²Surgeon of the Orthopedics and Traumatology, Department of Orthopedics and Traumatology, İstanbul University Medical Faculty, İstanbul.

³Surgeon of the Orthopedics and Traumatology, Department of Orthopedics and Traumatology, Şişli Etfal Training and Research Hospital, İstanbul.

⁴Assoc. Prof., Surgeon of the Orthopedics and Traumatology, Department of Orthopedics and Traumatology, Acıbadem University Atakent Hospital, İstanbul.

⁵Prof., Surgeon of the Orthopedics and Traumatology, Department of Orthopedics and Traumatology, İstanbul University Medical Faculty, İstanbul.

Address: Op. Dr. Okan Ozkunt, Acıbadem Üniversitesi Atakent Hastanesi Ortopedi ve Travmatoloji Kliniği, Halkalı, İstanbul
Tel.: 90 212 404 4048
Fax: 90 212 404 4445
E-mail: drdeto@gmail.com
Received: 1st October, 2014
Accepted: 11th December 2014

ABSTRACT:

Purpose: Analyze the prevalence of sacral screw loosening following posterior long segment instrumentation and fusion in adult spine.

Material methods: 66 patients who were diagnosed with adult spinal deformity with L5-S1 degeneration and treated using posterior instrumentation and PL or interbody fusion in our institute between 2003-2008 were included in the study. Anterior-posterior projection and lateral lumbosacral and CT projections were used for radiologic evaluation of patients. Patients were reviewed retrospectively under two groups: interbody fusion and posterolateral (PL) fusion. Standard lumbosacral X-ray was performed to evaluate pseudo arthrosis or sacral pedicle screw loosening. Preoperative and postoperative VAS scores were measured for functional assessment.

Results: Patients age were 69.1 (37-89) and mean follow-up was 8.8 years (6-11 years). 48 patients had degenerative spinal deformity and 18 patients had degenerative spondylolisthesis. We applied posterior instrumentation with posterolateral fusion in 50 patients and posterior instrumentation with interbody fusion in 16 patients. All procedure included L5-S1 segment. Level of posterior instrumentation mean was 5.9 (4-11). In PL fusion group 12 patients had sacral screw failure (24%) but no sacral screw failure in interbody fusion group ($p < 0,005$). VAS scores increased in both groups but in interbody fusion decrease was more prominent than PL fusion group ($p < 0,05$)

Conclusion: Interbody fusion of L5-S1 disc area for treatment of degenerative lumbar disease in patients with L5-S1 degeneration results positively on survival of the sacral pedicle screws.

Key words: Lumbar degenerative disease, instrumentation, sacral screws

Level of evidence: Retrospective clinical study, Level III.

ÖZET:

Amaç: Çalışmamızda yetişkin yaş grubunda uzun seviye posterior enstrümantasyon yapılan hastalarda cisimler arası füzyonun sakral vida gelişimi sıklığına etkisini araştırmayı amaçladık.

Materyal-Metod: Çalışmamızda 2003-2008 arasında, L5-S1 segmentinde dejenerasyonu bulunan ve posterior enstrümantasyonla tedavi edilen dejeneratif omurga tanılı 66 hasta retrospektif olarak değerlendirildi. Sadece posterolateral füzyon yapılanlar ve posterolateral füzyona L5-S1 cisimler arası füzyon eklenenler olarak iki gruba ayrılan hastalar radyolojik olarak ön-arka ve lateral lumbosakral grafiler ve bilgisayarlı tomografiyle değerlendirildi. Standart grafiler ile psödoartroz ve sakral vidada kırık ya da gevşeme değerlendirildi. Ameliyat öncesi ve sonrası fonksiyonel değerlendirmede VAS skoru kullanıldı. İstatistiksel analizler için SPSS (Statistical Package Social Sciences for Windows 12.0) programı kullanıldı. $p < 0,05$ sonucu istatistiksel anlamlı olarak değerlendirildi.

Sonuçlar: Hastaların ortalama yaşı 69.1 (37-89) ve ortalama takip süresi 8,8 yıl (6-11 yıl) idi. 48 hastada dar kanalın eşlik ettiği dejeneratif omurga ve 18 hastada dejeneratif spondilolistezis bulunmaktaydı. 50 hastaya uzun segment posterior enstrümantasyon ile birlikte posterolateral füzyon, 16 hastaya ise uzun segment enstrümantasyon ve L5-S1 cisimler arası füzyon uygulandı. Ortalama posterior enstrümantasyon seviyesi 5.9 (4-11) idi. Sonuçta, cisimler arası füzyon uygulanan grupta sakral vidalarda yetmezlik görünmezken, diğer grupta 12 hastada (% 24) gevşeme görülmekteydi. ($p < 0.05$) Klinik olarak, cisimler arası füzyon yapılan grupta VAS skoru istatistiksel olarak daha iyiydi. ($p < 0.05$)

Çıkarımlar: Lomber dejeneratif omurga hastalığının tedavisinde L5-S1 seviyesinde yapılan interbody füzyon uzun seviye enstrümantasyon yapılan hastalarda sakral pedikül vidasının gevşemesini azaltması ve daha iyi klinik sonuçlar sağlaması nedeniyle tercih edilebilir bir yöntemdir.

Anahtar Kelimeler: Lomber dejeneratif hastalığı, enstrümantasyon, sakral vida

Kanıt Düzeyi: Retrospektif klinik çalışma, Düzey III

INTRODUCTION:

During degeneration process morphologically vertebrae goes through dysfunction, instability and immobilization. After the degeneration a series of complex pathologies like subchondral sclerosis, osteophyte formation, convergence in anterior vertebral body, and spinal stenosis could be observed^{11,17,20}. In the degenerative process L5-S1 disc is most commonly affected but addition of this level to the fusion during lumbar vertebral surgery is still debated¹ Stopping the fusion at L5 level during surgical treatment, preserve range of motion in L5-S1 level. On the other hand, degeneration progressing in this level negatively affects the functional outcomes. Adding S1 level to the fusion contains risks like pseudoarthrosis depending on the procedure. It is reported that sacral pedicle screws may fail and anterior fusion might be added to posterior fusion to prevent this situation¹¹.

Aim of our study is show the effects of addition of anterior fusion to the procedure in patients with long segment fusion in which sacrum is included on survival of sacral pedicle screws.

PATIENTS AND METHODS:

66 patients who were diagnosed with adult spinal deformity with L5-S1 degeneration and treated using posterior instrumentation and PL or interbody fusion in our institute between 2003 and 2008 were assessed retrospectively.

Inclusion criteria was at least 4 levels fusion including L5-S1 segment for degenerative vertebrae, and in order to assess the survival of S1 screw at least years of follow up. Patients with revision surgery and short segment fusion were not included in the study.

Patients were evaluated in to groups: patients with posterolateral fusion, and patients with interbody fusion at L5-S1 disc space additional to posterior fusion. In patients included in the study posterolateral interbody fusion technique was employed for interbody fusion.

Patients files were retrospectively evaluated and clinical examination findings, VAS scores, surgery information, and complication were reviewed. Radiological evaluation was conducted from antero-posterior and lateral x-rays, CT and MRI. In the control x-rays fractures in the sacral pedicle screw or radiolucent area around the screw is accepted as loosening of the screw. For the final clinical evaluation patients VAS scores were considered.

For statistical analysis SPSS (Statistical Package Social Sciences) for Windows 12.0 program was employed. For comparison of quantitative data student t-test, and for qualitative data chi-square tests were used. $P < 0.05$ was accepted as statistically significant.

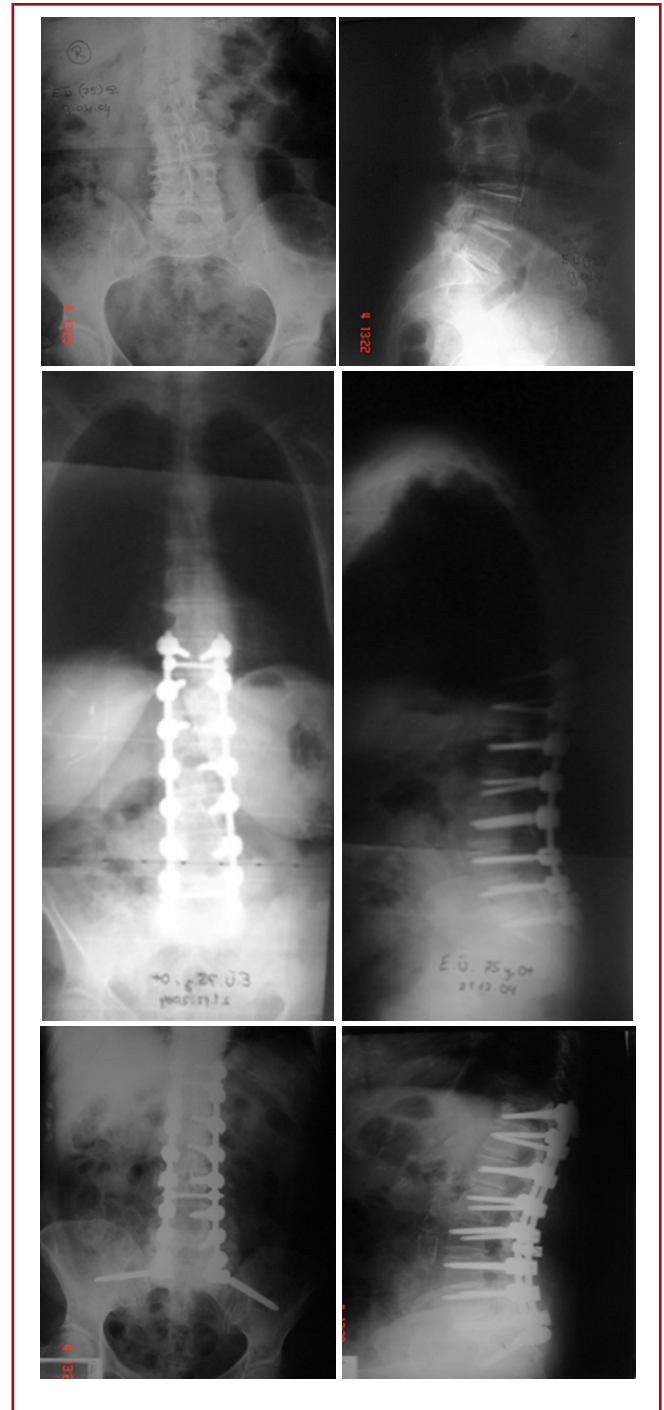


Figure-1. (a,b) A 75 years old female patient with degenerative lumbar vertebrae, preoperative x-rays show (c, d) degeneration at L5-S1 level. Patient was treated with posterior instrumentation with T11-S1 posterior fusion. (e, f) In the follow ups due to screw loosening and pain complaints revision surgery was performed.

RESULTS:

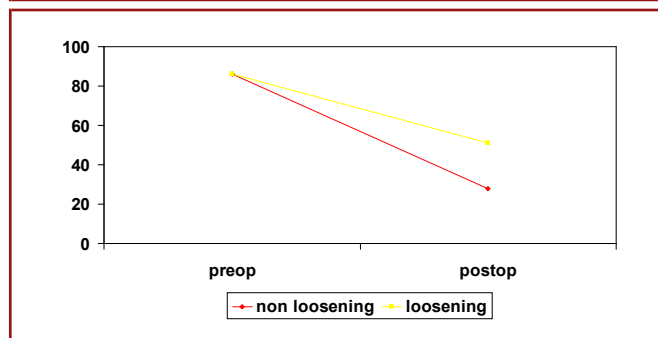
Average age of the patients included in the study was 69 (37–89) years and average follow up period was 8.8 (6-11) years. Patients' diagnosis was degenerative vertebrae accompanied by

spinal stenosis (48 patients) and degenerative spondylolisthesis (18 patients). Choice of surgical procedure was long segment posterior instrumentation with posterolateral fusion in 50 patients, and long segment instrumentation with L5-S1 fusion in 16 patients. Average of posterior instrumentation levels was 5.9⁴⁻¹¹.

In 12 patients included in the study, sacral pedicle screw insufficiency was observed (Figure-1). Sacral pedicle screw insufficiency was observed in 12 of the 50 patients (24%) who received posterior instrumentation and fusion, but in added interbody fusion group no sacral pedicle insufficiency was observed. When both groups were compared for screw loosening results of interbody fusion group was significantly better ($p < 0,05$).

Clinical evaluation of the patients using VAS scores revealed preoperative VAS scores in posterior fusion group was 8.2 and postoperatively 5.1 ($p < 0,05$). In the group with added interbody fusion preoperative VAS scores were 8.3 and postoperatively 3.6 ($p < 0,05$). When both groups are compared VAS scores of interbody fusion was significantly better ($p < 0,05$)(Table-1).

Table-1. Diagram showing changes in VAS scores according to the S1 screw loosening condition.



In two of our cases dural injury repaired during surgery and superficial infection treated with antibiotics were observed.

DISCUSSION:

In degenerative vertebral diseases L5-S1 degeneration effects the prognosis of the disease. In the meta-analysis of Sardar et al. reported that in case the fusion is stopped at the level of L5 during fusion complication rate was 23.5% but if patient had L5-S1 degeneration and this level is included in the fusion

complication rate was 53%¹⁶. Addition of L5-S1 level to the fusion is not recommended in when deformity includes lumbar-sacral region, progressive deformity and instability conditions and how L5-S1 should be added to the treatment is still debatable⁸.

In the treatment of degenerative lumbar vertebrae, and in the patients treated with long segment fusion complication rates are significantly higher¹⁰. Technically instrumentation of the sacrum results in longer surgery time and increased bleeding¹². In cases which only posterior fusion was implemented when fusion level is chosen as S1 instead of L5 pseudo-arthrosis risk is significantly increased⁹. After pseudo-arthrosis development at L5-S1 level control of the movement in these segments could only be possible through sacral implants^{13,14}. If the fusion is not complete this overloading on the sacral implants will result in loosening or fracture of sacral pedicle screws. Cho et al. reported this rate in their series as 25%⁶. Again in the literature Kim et al. in their 144 case series reported screw loosening rate as 24%, Edward et al. reported as 42%^{7,12}. We in our study, in 50 patients treated with posterior instrumentation and fusion found screw loosening rate as 24%.

In the literature, in order to minimize L5-S1 movement and perform fusion it is shown that a better fastening method biomechanically is suggested, and interbody fusion techniques, lubricant proteins and iliac screws accompanying sacral screws are described in the literature with success^{2,4,6,7,16,18,19}. In fusion only from the posterior is insufficient and requirement for an anterior support bring up the idea for a 360 degrees fusion and to regain sagittal balance interbody fusion is suggested¹⁵. In the studies from the literature, in patients with L5-S1 interbody fusion it was shown that pseudo-arthrosis rates are significantly smaller^{5,7,10,12}. After the achievement of L5-S1 fusion clinical and functional results were reportedly better with less observed complications⁵. Results we obtained in our study are in conformity with the literature. In patients whom interbody fusion is added to the procedure VAS scores were significantly higher. In cases with achieved fusion no sacral screw complications were observed. Statistically significantly, in cases with added interbody fusion long term radiological and clinical outcomes are superior. But as depicted in the literature surgery times are prolonged and bleeding was increased.

In the treatment of lumbar degenerative vertebral diseases in the case of inclusion of L5-S1 level to the fusion, application of interbody fusion has significant and beneficial effects on sacral pedicle screw survival in the long term.

REFERENCES:

1. Akbarnia BA, Ogilvie JW, Hammerberg KW. Debate: degenerative scoliosis: to operate or not to operate. *Spine* 2006; 31: S195-201.
2. Bridwell KH, Glassman S, Horton W, Shaffrey C, Schwab F, Zebala LP, Lenke LG, Hilton JF, Shainline M, Baldus C, Wootten D. Does treatment (nonoperative and operative) improve the two-year quality of life in patients with adult symptomatic lumbar scoliosis: a prospective multicenter evidence-based medicine study. *Spine* 2009; 34: 2171-2178.
3. Brown S, Ward S, Harkowitz H, Garfin S, Eismont F, Bell GR, Balderstone RA. *The intervertebral disc: Normal, aging and pathologic*. In: Brown S, Ward S, Harkowitz H, Garfin S, Eismont F, Bell GR, Balderstone RA (Eds.) *Rothman-Simeone The Spine*. Sixth ed., Saunders-Elsevier, Philadelphia 2011; pp: 97-109.
4. Carreon LY, Puno RM, Dimar JR, 2nd, Glassman SD, Johnson JR. Perioperative complications of posterior lumbar decompression and arthrodesis in older adults. *J Bone Joint Surg* 2003; 85-A: 2089-2092.
5. Cho KJ, Suk SI, Park SR, Kim JH, Choi SW, Yoon YH, Won MH. Arthrodesis to L5 versus S1 in long instrumentation and fusion for degenerative lumbar scoliosis. *Eur Spine J* 2009; 18: 531-537.
6. Crawford LYC, Bridwell KH, Glassman SD. Long fusions to the sacrum in elderly patients with spinal deformity. *Eur Spine J* 2012; 21(11): 2165-2169.
7. Edwards CC, 2nd, Bridwell KH, Patel A, Rinella AS, Berra A, Lenke LG. Long adult deformity fusions to L5 and the sacrum. A matched cohort analysis. *Spine* 2004; 29: 1996-2005.
8. Emami A, Deviren V, Berven S, Smith JA, Hu SS, Bradford DS. Outcome and complications of long fusions to the sacrum in adult spine deformity: luque-galveston, combined iliac and sacral screws, and sacral fixation. *Spine* 2002; 27: 776-786.
9. Glassman SD, Hamill CL, Bridwell KH, Schwab FJ, Dimar JR, Lowe TG. The impact of perioperative complications on clinical outcome in adult deformity surgery. *Spine* 2007; 32: 2764-2770.
10. Horton WC, Holt RT, Muldowny DS. Controversy. Fusion of L5-S1 in adult scoliosis. *Spine* 1996; 21: 2520-2522.
11. Keller A, Hayden J, Bombardier C, van Tulder M. Effect sizes of non-surgical treatments of non-specific low-back pain. *Eur Spine J* 2007; 16: 1776-1788.
12. Kim YJ, Bridwell KH, Lenke LG, Cho KJ, Edwards CC, 2nd, Rinella AS. Pseudarthrosis in adult spinal deformity following multisegmental instrumentation and arthrodesis. *J Bone Joint Surg* 2006; 88-A: 721-728.
13. Kostuik JP, Hall BB. Spinal fusions to the sacrum in adults with scoliosis. *Spine* 1983; 8: 489-500.
14. Kwon BK, Elgafy H, Keynan O, Fisher CG, Boyd MC, Paquette SJ, Dvorak MF. Progressive junctional kyphosis at the caudal end of lumbar instrumented fusion: etiology, predictors, and treatment. *Spine* 2006; 31: 1943-1951.
15. Liu X, Wang Y, Qiu G, Weng X, Yu B. A systematic review with meta-analysis of posterior interbody fusion versus posterolateral fusion in lumbar spondylolisthesis. *Eur Spine J* 2014; 23: 43-56.
16. Sardar ZM, Ouellet JA, Fischer DJ, Skelly AC. Outcomes in adult scoliosis patients who undergo spinal fusion stopping at L5 compared with extension to the sacrum. *Evidence-based spine-care J* 2013; 4: 96-104.
17. Spivak JM, Connolly PJ. Pathophysiology of degenerative disc disease and related symptoms. In: Rao RD, Bagaria V (Eds.), *OKU-3 Spine*. Third ed., American Academy of Orthopaedic Surgeons, Illinois, 2006; pp: 35-40.
18. Tsuchiya K, Bridwell KH, Kuklo TR, Lenke LG, Baldus C. Minimum 5-year analysis of L5-S1 fusion using sacropelvic fixation (bilateral S1 and iliac screws) for spinal deformity. *Spine* 2006; 31: 303-308.
19. Vaccaro AR, Whang PG, Patel T, Phillips FM, Anderson DG, Albert TJ, Hilibrand AS, Brower RS, Kurd MF, Appannagari A, Patel M, Fischgrund JS. The safety and efficacy of OP-1 (rhBMP-7) as a replacement for iliac crest autograft for posterolateral lumbar arthrodesis: minimum 4-year follow-up of a pilot study. *Spine J* 2008; 8: 457-465.
20. Wang JMPHR. Current treatment strategies for the painful lumbar motion segment: posterolateral fusion versus interbody fusion. *Spine* 2005; 30(16 Suppl): S33-43.