

SURGICAL CORRECTION OF ADOLESCENT IDIOPATHIC SCOLIOSIS BY MEANS OF CD INSTRUMENTATION

M. S. Filipovic, Z. B. Milinkovic, V. Basara

Special Hospital for Orthopaedic Surgery "Banjica", Belgrade, Yu.

Our experience includes 30 operations on 30 patients with idiopathic scoliosis, 22 of which were females and 8 males. Minimum follow-up period was one year and average age of the patients 13 years (11-16). We have had 13 patients with thoracic curvature (instrumentation T5-L1), 6 patients with double (thoracic+lumbar) curvature (instrumentation T5-L4), 5 patients with thoracolumbar curve (instrumentation T10-L4) and 5 patients having curvature in the lumbar region (instrumentation T10-L4).

Preoperative angulation ranged from 55° to 95° (mean initial angulation being 65°). Postoperative angulation was 16° (12°-30°), or 74% correction of the average initial angulation. Preoperative rotation measured by Perdriolle ruler was 40° (25-45°) and postoperative rotation 30° (15-35°). Achievement of normal thoracic kyphosis in cases of thoracic lordosis (13 cases) was satisfactory although not spectacular. Lumbar lordosis was preserved in all cases. Average loss of the correction at follow-up examinations (one year after operation) was 5° (2-7°). Solid bone calus occurred 9-10 months after the operation and can be seen on lateral X-rays of the spine. In all cases we performed spinal cord monitoring by using intra-operative awakening and test of foot movement. No abnormalities were found during the wake-up test. Complications occurred in 3 cases and they mainly referred to hook dislocations. From the aesthetic aspect, all the obtained results were satisfactory. In case where initial angulation was 95° thoracophrenolumbotomy with anterior fusion was done in the first stage and posterior fusion with CD instrumentation in the second stage. All patients were ambulatory in the second week after operation, without any external support and returned to their school or family activities.

Key Words: CD instrumentation, posterior fusion, scoliosis.

MATERIALS AND METHODS

Cotrel-Dubouset (CD) instrumentation is a new segmental instrumentation of the spine. It was designed to allow selective and three-dimensional correction of spinal deformities and strong fixation without sublaminar wiring. Main advantages of CD instrumentation are: three-dimensional correction in flexible thoracic lordoscoliosis, thoracolumbar and double major curves (thoracic+lumbar), high rigidity and no postoperative cast or brace. It presents a challenge to all spinal surgeons engaged in the surgical treatment of spinal deformities. Results obtained by this method will contribute in determining its precise possibilities and its place in the arsenal of tools necessary for the treatment of spinal deformities.

We have been using CD instrumentation since 1986 though 1989, 45 patients in our hospital were submitted to posterior spinal fusion with CD instrumentation. Our analysis includes 30 cases which were followed-up for more than one year. They were all cases of adolescent idiopathic scoliosis. The hospital chart, pre- and postoperative x-rays, anesthetic record and clinical photographs of this 30 patients were reviewed. Preoperative and postoperative rotation was measured by Perdriolle ruler.

Type of the Curvature	No. of patients
Thoracic, flexible lordoscoliosis	13 (Inst. T5-L1)
Double (thoracic + lumbar)	7 (Inst. T5-L4)
Thoracolumbar	5 (Inst. T10-L4)
Lumbar	5 (Inst. T10-L4)

M. S. Filipovic, Z. B. Milinkovic, V. Basara

Special Hospital for Orthopaedic Surgery "Banjica",
Belgrade, Yu.

Surgery was carried out under hypotensive general anesthesia with the patient on a Cotrel operative table

using traction of 10 to 15 kg. Spinal cord monitoring by wake-up test was used routinely.

No postoperative external immobilization was used. Ambulation began on the seventh postoperative day. Patients were discharged from the hospital 14 days after surgery. Full activities were allowed after five months.

RESULTS

The average preoperative curvature was 65° (range 55-95°). The average postoperative angulation was 16° (range 12-30°). Preoperative rotation was 40° (range 25-45°) and postoperative rotation 30° (range 15-35°). Lumbar lordosis was maintained in all cases including 5 cases with lumbar scoliosis where lordosis was flattened. We tried to creat lordosis. Preoperative kyphosis, measured by the Cobb angle, was 15°. Postoperative kyphosis was 25°.

The average operating time in the beginning of our work was four and a half hours. Average operating time now is between three and four hours. The average intraoperative blood loss was 1100 ml. (range 400-1800 ml.).

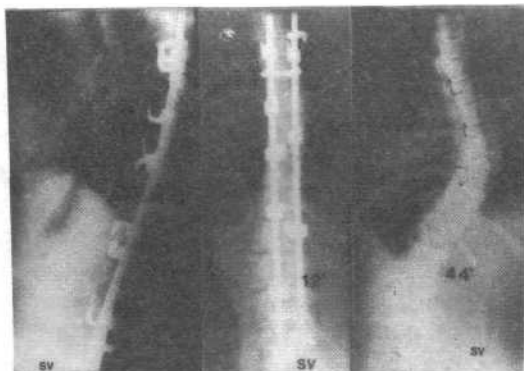


Fig.2
Same patient as in Fig.1, one year after operation. The correction is completely maintained.

Fig.1-B
Postoperative AP roentgenogram one year after operation of S.C. showing 8° right thoracic curve and 12° of lumbar curvature. No loss of initial correction.

Fig.1-A
Anteroposterior radiograph of S.C., a 13-year-old girl. Major Right thoracic flexible curve of 55° and minor lumbar curve of 44°.

Complications occurred in 3 cases and they mainly referred to hook dislocations. In one of these cases, closed upper pedicular hook on the concave side, migrated under the processus transversus. In the remaining two cases lower laminar hook, on the convex side, caused a fracture of the lamina and resulted in dislocation.

There were no intraoperative complications and up-to-day there were no wound infections or neurological lesions. In the postoperative period of 13 cases with right thracic losdoscoliosis we have noticed elevation of the left shoulder. We initiated a gentle physical therapy and were able to obtain balance of the shoulder.

Average loss of the correction was 5° (range 2°-7°).

DISCUSSION

Our opinion is that CD instrumentation is the method of choice in the treatment of spinal deformities. Harrington's procedure is a very safe operation with only 0.70 % of acute neurological complications. Modifications of Harrington's procedure improve the correction and rigidity but do not improve the coronal and sagittal plane correction.

The advantages of anterior instrumentation are: good angular and rotatory correction, objective partial correction of the secondary structural curve and shortened fusion area. Disadvantages of anterior instrumentation are: over correction, failure of instrumentation, non-union and postoperative bracing.

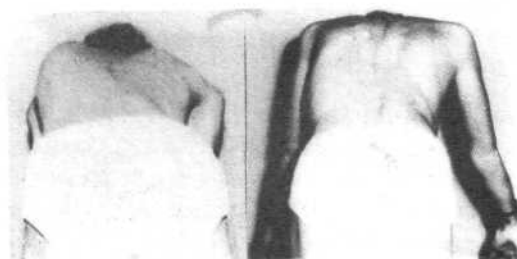


Fig.3-A

Fig.3-B

A. The back of the patient before the operation.
B. Same girl after the operation.

CD instrumentation combines advantages of Harrington's procedure and those of anterior spinal instrumentation and eliminating all their disadvantages. Angular correction with CD instrumentation is somewhat less good than that achieved by anterior instrumentation but much better than that achieved by Harrington's method. Derotation of rotated vertebrae, although not so spectacular as that with Zielke's method, with maintenance of sagittal curves, makes CD method superior to other methods. No need for posterior external immobilization is of great importance for adolescent patients.

However, we think that in large curvatures, those above 80-90°, application of CD instrumentation should be selective and extremely careful. It may often require a two act surgery. In cases of large curvatures (around 100°) we perform surgery in two acts is then followed by plaster jacket immobilization for a period of 6 months.

Aesthetic appearance of patients after CD instrumentation is extremely good. No additional resection of gibbosity is necessary.

Follow-up period of one year is too early to discuss non-union rates. CD instrumentation appears to be a safe method which effectively corrects the scoliotic curves.

REFERENCES

- 1 . Bergoin, M., Bollini, G., Hornung, H., Tallet, M.J., and Gennari, M.J.: Is the Cotrel-Dubousset Really Universal in the Surgical Treatment of Idiopathic Scoliosis? *Journal of Pediatric Orthopaedics*, 45-48, Raven Press, Ltd., New-York, 1988.
- 2 . Birch, G. John, Herring, A. John, Roach, W. James, and Johnston, E. Charles: Cotrel-Dubousset Instrumentation in Idiopathic Scoliosis, A Preliminary Report, *Clin. Orthop.*, 24-29, 227, 1988.
- 3 . Cotrel, Y., and Dubousset, J.: Nouvelle technique d'osteosynthese rachidienne segmentaire par voie posterieure. *Rev. Chir. Orthop.* 70: 489, 1984.
- 4 . Cotrel, Y. Dubousset, J., and Guillaumat, M.: New Universal Instrumentation in Spinal Surgery. *Clin. Orthop.*, 227: 10, 1988.
- 5 . Cotrel-Dubousset Instrumentation, proceeding of the international congress, Sauramps Medical, Paris, 1985.
- 6 . Chopin, D.: Personal communications, Beograd, Berck Plage, 1987, 1988.