

INCIDENCE OF ASYMPTOMATIC RECURRENT LARYNGEAL NERVE PALSY FOLLOWING ANTERIOR CERVICAL SPINE SURGERY

● Mehmet Volkan Aydın¹, ● Deniz Şirinoğlu¹, ● Ozan Başkurt², ● Nihan Altıntepe³, ● Gökhan Perçinoğlu¹, ● Serap Karacalar⁴, ● Yavuz Uyar⁵

¹University of Health Sciences Turkey, Prof. Dr. Cemil Taşcıoğlu City Hospital, Clinic of Neurosurgery, İstanbul, Turkey

²Kızıltepe State Hospital, Clinic of Neurosurgery, Mardin, Turkey

³Kızıltepe State Hospital, Clinic of Anesthesiology and Intensive Care, Mardin, Turkey

⁴University of Health Sciences Turkey, Prof. Dr. Cemil Taşcıoğlu State Hospital, Clinic of Anesthesiology and Intensive Care, İstanbul, Turkey

⁵University of Health Sciences Turkey, Prof. Dr. Cemil Taşcıoğlu State Hospital Clinic of Otorhinolaryngology-Head and Neck Surgery, İstanbul, Turkey

ABSTRACT

Objective: Anterior cervical spine surgery (ACSS) has become the most preferred surgical approach for the subaxial cervical spine. To understand the laryngeal complications, the recurrent laryngeal nerve (RLN) is the most important anatomical landmark. Because RLN palsy are often subclinical, there are few data on the incidence of total RLN palsy, and for this reason, asymptomatic RLN injuries are thought to be even more common. In this prospective study, we aimed to determine the incidence of asymptomatic RLN palsy after ACSS.

Materials and Methods: A total of 46 patients who underwent ACSS between November 4, 2019 and June 30, 2021 during the corona disease pandemic, were enrolled in this single-centre, prospective study. Only anteromedial approaches were evaluated. Preoperative video laryngoscopic intubation was performed before ACSS to assess the vocal cords. Indirect laryngoscopy was performed to assess postoperative status.

Results: ACSS was performed at one level in 36 patients and at two levels in 10 patients. The average duration of the procedure was 128.13 minutes and the average retraction time was 69.19 minutes. Dysphonia after ACSS was observed in 3 patients (6.52%), whereas asymptomatic RLN palsy was noted in only 2 patients (4.34%). These patients showed only unilateral vocal cord paralysis on indirect laryngoscopy, which was consistent with RLN injury.

Conclusion: The RLN is susceptible to injury during ACSS. Our relatively low rate of asymptomatic RLN paresis may be due to respect for the tissue, careful handling during dissection, and the use of periodically released retraction.

Keywords: Anterior cervical spine surgery, asymptomatic recurrent laryngeal nerve palsy, dysphonia, recurrent laryngeal nerve

INTRODUCTION

The anterior approach has been used for 70 years to access the cervical spine, particularly the vertebral body between C3 and T1⁽¹⁾. With the development of internal fixation, instrumentation, and retraction devices, as well as the development of technology with imaging and microscope as part of the surgical treatment, anterior cervical spine surgery (ACSS) has become the most preferred surgical approach for the subaxial cervical spine⁽²⁾. The trachea and esophagus, the recurrent laryngeal nerve (RLN), the superior laryngeal nerve, the cervical sympathetic trunk, and the accessory spinal nerve have been implicated in this approach^(3,4). In particular, to understand laryngeal

complications after ACSS, the anatomy and nerve supply of the larynx should be studied⁽⁵⁾.

The RLN innervates the posterior cricothyroid muscles, the only muscles that can open the vocal cords⁽⁶⁾. Thus unilateral RLN paresis results in unilateral paralysis of the vocal cords, causing an inability to adduct or abduct. Inadequate laryngeal closure during phonation results in a breathy and raspy voice, hoarseness with increased vocal effort, and fatigue⁽⁷⁾. Because RLN palsies are often subclinical, data on the incidence of total RLN palsies are limited and while asymptomatic RLN injuries have been hypothesized to be even higher⁽⁴⁾. In this prospective study, we aimed to determine the incidence of asymptomatic RLN palsy after ACSS using preoperative video laryngoscope intubation and postoperative indirect laryngoscopy.

Address for Correspondence: Ozan Başkurt, Kızıltepe State Hospital, Clinic of Neurosurgery, Mardin, Turkey

Phone: +90 533 464 25 50 **E-mail:** ozanbskrt@gmail.com **Received:** 27.06.2022 **Accepted:** 11.08.2022

ORCID ID: orcid.org/0000-0003-1021-6529



MATERIALS AND METHODS

This study was approved by the University of Health Sciences Turkey, Okmeydanı Training and Research Hospital Ethics Committee (approval date no: 24/10/2019, approval no: 48670771-514.10). A total of 46 patients undergoing ACSS between November 4, 2019, and June 30, 2021, were enrolled in this prospective single-centre clinical trial. The study population was determined with G*power program by taking $\alpha=0.05$, power $(1-\beta)=0.90$.

Inclusion Criteria: Patients who underwent surgery with the anterior cervical approach, were over 18 years of age and younger than 65 years, and consented to participate in the study were included.

Exclusion Criteria: Exclusion criteria were patients younger than 18 years or older than 75 years, patients with previous vocal cord pathology, difficult intubation history, patients with American Society of Anesthesiologists III (ASA III) and above, and patients who did not consent.

Preoperative Evaluation: Patient age and sex, ASA score, height, weight, and body mass index (BMI) were noted. Comorbidities and surgical history, especially previous cervical spine surgery, were reviewed in detail.

Anesthesia: Patients placed supine on the operating table were carefully intubated with a video laryngoscope. The vocal cords were thus examined before intubation, and if pathology was present, the patient was excluded from the study. During intubation, excessive flexion and extension of the neck was avoided. Endotracheal tube (ETT) cuff pressures (ETCPs) were measured. The ETT was set to a cuff pressure of 20 mmHg or less.

Surgical Procedures: Only the anteromedial approaches were evaluated. After careful dissection and adequate mobilization of soft tissues using hand retractors, the surgical field was routinely created with the retraction of trachea and esophagus medially, the sternocleidomastoid muscle and carotid sheath laterally up to the prevertebral fascia. We had avoided sharp dissections and stay away from the tracheoesophageal groove. The RLN was not visualized in any case. After palpation of the vertebral body, the prevertebral fascia and anterior longitudinal ligament were separated from the midline and a subperiosteal release of the longus colli muscle was obtained. Caspar (Aesculap) and Cloward (Codman) automatic retractor systems are routinely used as self-retaining automatic retractors in our clinic for ACSS, so the types of retraction were standardized. The cuff of the ETT was deflated after retractor insertion and then re-inflated to less than 20 mmHg. Anterior cervical discectomy and fusion (ACDF) with or without corpectomy with anterior plate was performed. The surgical technique during the operation and the structural differences in the cervical spine of the patients were recorded.

Postoperative Evaluation: Complications of postoperative extubation were noted. Perioperative methylprednisolone administration if needed was added to the case report forms. Routine radiographs of the cervical spine were evaluated after mobilization on the first postoperative day. Neck and cranial nerve examinations were performed. In the final stage, a detailed examination of the vocal cords was performed by the department of otolaryngology via the indirect laryngoscopy (Figure 1).

Statistical Analysis

The SPSS (Statistical Package for the Social Sciences) program (IBM Statistics version 25.0 inc., an IBM Co., Somers, NY) for Windows was used for statistical analysis. Descriptive statistics: Numbers and percentages for categorical variables, mean, standard deviation, minimum, maximum, and median for numerical variables. Subgroup analyzes were performed with the Mann-Whitney U test and interpreted with the Bonferroni correction. Rates in groups were compared with the chi-square test. The statistical alpha significance level was accepted as $p<0.05$.

RESULTS

In our neurosurgery department, a total of 64 patients underwent ACSS during the pandemic corona virus disease-2019 (COVID-19). Four patients older than 75 years, 2 patients with preoperative vocal cord pathology detected during intubation with the video laryngoscope, 2 patients with difficult intubation history, 5 patients who did not consent to the study, and 5 patients with ASA III and above were excluded. A total of 46 patients were evaluated. Twenty-two patients were women and 24 were men. The age of the patients ranged from 23 to 74 years, with a mean of 46.87 years. The BMI of the patients ranged from 18.92 to 37.33, with a mean of 28. A total of 14 patients (30%) had a previous comorbidity. Among these patients, 4 patients had a history of hypertension, 3 had diabetes mellitus, and 3 had both. Two patients had chronic obstructive pulmonary disease, and 2 patients had neurodegenerative disease. Three patients had prior ACDF, and 3 patients had prior thyroidectomy. Patients

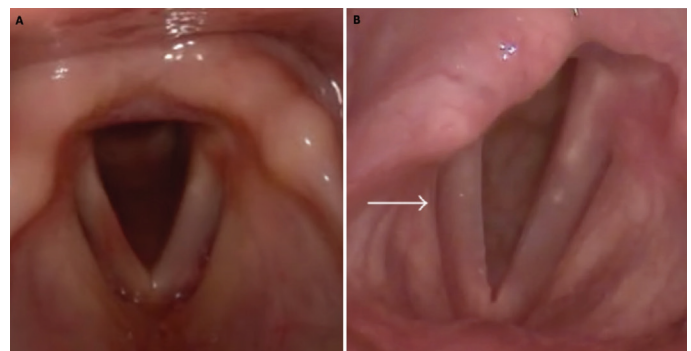


Figure 1. Postoperative assessment during indirect laryngoscopy
 A. Non-pathologic vocal cords
 B. Pathologic; movement of the right vocal cords is restricted

were hospitalized for a mean of 5 days (range, 2-12 days). ACDF with cage/prosthesis was performed in 40 patients, ACDF with corpectomy in 4 patients, ACDF with an anterior plate in 2 patients. Surgery was performed at one level in 36 patients and at two levels in 10 patients. The levels involved were C3-C4 in 3 patients, C4-C5 in 12 patients, C5-C6 in 24 patients, and C6-C7 in 17 patients. Forty-three patients operated in the radiculopathy clinic. Arm pain was localised on the left side in 23 patients, on the right side in 13, and on both sides in 7. In 38 patients, a right-sided approach was chosen. A transverse or oblique incision through the skin and subcutaneous fat was made on the selected side. The average duration of the procedure was 128.13 minutes (range, 85-240 minutes). The average retraction time was 69.19 minutes (range, 30-130 minutes). The range of Cloward retraction was between 2-3 cm in 33 patients and between 3-4 cm in 13 patients (average 2.8 cm). Postoperative anesthetic complication was observed in 2 patients: Postintubation bronchospasm. A total of 3 patients had postoperative dysphonia (6.52%). Methylprednisolone was administered in these patients. No aspiration or dysphagia was observed. Dysphonia developed in 2 female and 1 male patients with ACDF with cage. Two of them underwent surgery at a single level: one at the C5-6 level and the other at the C6-7 level, and the last patient underwent surgery at C4-5 and C5-6. These patients showed only unilateral vocal cord paralysis consistent with RLN injury on indirect laryngoscopy. The observed RLN complication resolved spontaneously in all these patients in our series. The mean recovery time of dysphonia was 3 weeks (range, 2-5 weeks). Asymptomatic RLN palsy was found in only 2 patients (4.34%) who underwent surgery at multiple levels: one involved levels C5-6 and C6-7, and the other involved levels C4-5 and C5-6. The average duration of surgery in these 2 patients was 200 minutes, and the average retraction time was 57.5 minutes. The Cloward retraction range in both was between 3-4 cm.

DISCUSSION

RLN injuries are frequently reported as ACSS-related complications^(4,8,9). Two terms for RLN injury appear in the literature: the incidence of clinical dysphonia and vocal cord paralysis as a result of RLN palsies. This is the first prospective study to show the incidence of actual asymptomatic RLN palsy after ACSS.

The proposed mechanisms of RLN injury were direct injury to the nerve during exposure and traction injuries^(1,10,11). Traction injury can be accepted as stretch-induced neuropraxia⁽¹⁾. Incorrect placement of the retractor or excessive retraction of the larynx, entrapment of the nerve between the inflated cuff of the ETT, and postoperative edema are the main types of these injuries in which neuropraxia is caused by local ischemia⁽¹²⁾.

Revision surgery and surgery requiring more extensive dissection or retraction had a significantly increased rate of injury^(13,14). In a prospective study conducted by Curry and

Young⁽¹⁵⁾, laryngoscopic examinations were performed before revision ACDF and 17.3% (4 of 23 patients) of patients had abnormalities. Paniello et al.⁽¹⁶⁾ found that of 47 patients who underwent screening for revision ACSS, 13 (26%) had laryngeal abnormalities, including 11 cases (22%) who had vocal cord paresis, 5 of whom were asymptomatic. In our cases, no clinical or subclinical RLN palsy was observed in any of the patients with previous ACDF surgery.

ETCPs and their effects on the mechanism of injury at the RLN have been described in the literature by Apfelbaum et al.^(17,18). ETTs can cause nerve ischemia by exerting pressure on the RLN and submucosal surface⁽¹⁹⁾. In contrast, another prospective study by Audu et al.⁽²⁰⁾ concluded that ETT cuff deflation/reflation and pressure adjustment did not reduce the incidence of RLN injury in ACSS. Nevertheless, in our cases, the ETT was adjusted to a cuff pressure of 20 mmHg or less for standardization. And ETCP monitoring with deflation during retraction was also used in all patients. The reported incidence of RLN injury in the early postoperative period after ACSS ranged from 0 to 15.4% in prospective studies and from 0.2 to 7.9% in retrospective studies^(8,9,14,21-26). Zeidman et al.⁽²⁷⁾ reported a 0.2% retrospective incidence of RLN palsy in 4,589 patients who underwent surgical procedures such as anterior cervical discectomy, ACDF, corpectomy, laminectomies, posterior arthrodesis, laminoplasty, and cervical plating. A systematic review by Tan et al.⁽¹⁴⁾ found that the incidence of RLN palsy with vocal cord palsy after ACSS ranged from 0.2 to 24.2%. Gokaslan et al.⁽²⁸⁾ conducted a multicenter retrospective study as part of the AOSpine North America Clinical Research Network and reported that the incidence of RLN palsy after subaxial cervical spine surgery ranged from 0.6 to 2.9% between centers. Consistent with the literature, the incidence of clinical RLN palsy in our study was 6.52%.

Because RLN palsy is often subclinical, data on the incidence of total RLN palsy are limited, whereas asymptomatic RLN injuries were thought to be even more common⁽⁴⁾.

The actual incidence of RLN palsy is understudied in the literature, with some surgeons accepting it as a minor symptom, short duration of this symptom, or even mostly asymptomatic. RLN injury is usually asymptomatic but can manifest in a spectrum ranging from hoarseness, vocal fatigue, dysphonia, impaired phonation, dysphagia, aspiration to impaired cough reflex, airway obstruction, stridor, and permanent tracheostomy⁽²⁹⁾. Jung et al.⁽⁴⁾ used preoperative and postoperative direct laryngoscopy in patients underwent ACSS, including ACDFs, cervical corpectomies, and anterior osteosynthetic fusion procedures. They found that the incidence of asymptomatic and symptomatic RLN palsy was 24.2%, with 15.9% of their patients developing clinically silent RLN palsy after surgery. Dimopoulos et al.⁽³⁰⁾ used intraoperative laryngeal electromyography to predict the development of RLN palsy in 298 patients who underwent ACDF. They detected significant laryngeal activity in 14.4% of patients, of whom 2.3% developed RLN palsy. Our incidence of subclinical RLN injury was 4.34%. We have assumed

the intensity of retraction to be the sum of the retraction time and the degree of retraction. Retraction must be applied for a short period (<175 minutes) and relaxed intermittently⁽³¹⁾. We adhered to this rule of timing for retraction. The average retraction time in our cases was 69.19 minutes. Although our durations were not exceeded, RLN paresis occurred. Some authors prefer the use of hand-held retractors where the pressure can be controlled⁽¹¹⁾. But with experienced hands, static self-holding retractors, which we prefer, can also be an effective and noninjurious method. In the Weisberg et al.⁽¹⁾ cadaver model that supported stretch neuropathy, stretch was significant only when the retractor opening was greater than 3 cm, which corresponds to the degree of traction. In our cases, the width of the retractor opening is usually about 2.8 cm. The width of the retractor is limited by the placement of its blades under the longus colli muscle. Therefore, we placed the retractor sufficiently under the longus colli muscle to place it well. Possible explanations for our relatively low rate of asymptomatic RLN palsies could be respect for the tissue, care in handling blunt and sharp instruments, and use of careful, periodically released retraction.

Study Limitations

The limitation of our study is the small sample size. Because our study was conducted during the COVID-19 pandemic, the number of elective surgeries decreased. Given the quality-of-life-impairing consequences of vocal cord paralysis, prevention is important, no matter how low the incidence.

CONCLUSION

ACSS is the most commonly performed surgical procedure for subaxial cervical spine pathology. Serious complications await the surgeon if he does not pay attention to the course and location of the RLN during ACSS. In this single centre prospective study of asymptomatic RLN palsies after ACSS, the incidence was 4.34%. Avoiding overly wide retractor opening via the longus colli muscle anatomy and intermittent release of retraction could reduce the incidence of RLN palsy.

Ethics

Ethics Committee Approval: This study was approved by the University of Health Sciences Turkey, Okmeydanı Training and Research Hospital Ethics Committee (approval date no: 24/10/2019, approval no: 48670771-514.10).

Informed Consent: Written informed consents were obtained from patients included in this study.

Peer-review: Externally peer-reviewed.

Authorship Contributions

Surgical and Medical Practices: M.V.A., D.Ş., O.B., N.A., Y.U., Concept: M.V.A., D.Ş., Design: D.Ş., O.B., N.A., Data Collection or Processing: O.B., N.A., G.P., Analysis or Interpretation: M.V.A., S.K., Y.U., Literature Search: M.V.A., O.B., N.A., Writing: M.V.A., O.B., N.A., G.P.

Financial Disclosure: The authors declared that this study received no financial support.

Conflict of Interest: The authors have no conflicts of interest to declare

REFERENCES

1. Weisberg NK, Spengler DM, Netteville JL. Stretch-induced nerve injury as a cause of paralysis secondary to the anterior cervical approach. *Otolaryngol Head Neck Surg.* 1997;116:317-26.
2. Korinth MC. Treatment of cervical degenerative disc disease - current status and trends. *Zentralbl Neurochir.* 2008;69:113-24.
3. Lu J, Ebraheim NA, Nadim Y, Huntoon M. Anterior approach to the cervical spine: surgical anatomy. *Orthopedics.* 2000;23:841-5.
4. Jung A, Schramm J, Lehnerdt K, Herberhold C. Recurrent laryngeal nerve palsy during anterior cervical spine surgery: a prospective study. *J Neurosurg Spine.* 2005;2:123-7.
5. Yalcin B, Develi S, Tubbs RS, Poyrazoglu Y, Yazar F. Blood supply of the terminal part of the external branch of the superior laryngeal nerve. *Surg Today.* 2015;45:1160-5.
6. Yalcin B, Poyrazoglu Y. Recurrent laryngeal nerve. *Surg Radiol Anat.* 2012;34:571.
7. Dave BR, Devanand D, Zaveri G. Approach-Related Complications Following Anterior Cervical Spine Surgery : Dysphagia, Dysphonia, and Esophageal Perforations. In: *The ASSI Monographs: Complications in Spine Surgery.* 2018;1:33-47.
8. Riley LH Jr, Robinson RA, Johnson KA, Walker AE. The results of anterior interbody fusion of the cervical spine. Review of ninety-three consecutive cases. *J Neurosurg.* 1969;30:127-33.
9. Tew JM Jr, Mayfield FH. Complications of surgery of the anterior cervical spine. *Clin Neurosurg.* 1976;23:424-34.
10. Heese O, Schröder F, Westphal M, Papavero L. Intraoperative measurement of pharynx/esophagus retraction during anterior cervical surgery. Part I: pressure. *Eur Spine J.* 2006;15:1833-7.
11. Papavero L, Heese O, Klotz-Regener V, Buchalla R, Schröder F, Westphal M. The impact of esophagus retraction on early dysphagia after anterior cervical surgery: does a correlation exist? *Spine (Phila Pa 1976).* 2007;32:1089-93.
12. Cuello CMC, De Jesus O. Neurapraxia. [Updated 2021 Jul 31]. In: *StatPearls [Internet]. Treasure Island (FL): StatPearls Publishing; 2021 Jan-. Available from: <https://www.ncbi.nlm.nih.gov/books/NBK560501/>*
13. Beutler WJ, Sweeney CA, Connolly PJ. Recurrent laryngeal nerve injury with anterior cervical spine surgery risk with laterality of surgical approach. *Spine (Phila Pa 1976).* 2001;26:1337-42.
14. Tan TP, Govindarajulu AP, Massicotte EM, Venkatraghavan L. Vocal cord palsy after anterior cervical spine surgery: a qualitative systematic review. *Spine J.* 2014;14:1332-42.
15. Curry AL, Young WF. Preoperative laryngoscopic examination in patients undergoing repeat anterior cervical discectomy and fusion. *Int J Spine Surg.* 2013;7:e81-3.
16. Paniello RC, Martin-Bredahl KJ, Henkener LJ, Riew KD. Preoperative laryngeal nerve screening for revision anterior cervical spine procedures. *Ann Otol Rhinol Laryngol.* 2008;117:594-7.
17. Apfelbaum RI, Kriskovich MD, Haller JR. On the incidence, cause, and prevention of recurrent laryngeal nerve palsies during anterior cervical spine surgery. *Spine (Phila Pa 1976).* 2000;25:2906-12.
18. Kriskovich MD, Apfelbaum RI, Haller JR. Vocal fold paralysis after anterior cervical spine surgery: incidence, mechanism, and prevention of injury. *Laryngoscope.* 2000;110:1467-73.
19. Whited RE. A study of endotracheal tube injury to the subglottis. *Laryngoscope.* 1985;95:1216-9.

20. Audu P, Artz G, Scheid S, Harrop J, Albert T, Vaccaro A, et al. Recurrent laryngeal nerve palsy after anterior cervical spine surgery: the impact of endotracheal tube cuff deflation, reinflation, and pressure adjustment. *Anesthesiology*. 2006;105:898-901.
21. Razfar A, Sadr-Hosseini SM, Rosen CA, Snyderman CH, Gooding W, Abla AA, et al. Prevention and management of dysphonia during anterior cervical spine surgery. *Laryngoscope*. 2012;122:2179-83.
22. CLOWARD RB. The anterior approach for removal of ruptured cervical disks. *J Neurosurg*. 1958;15:602-17.
23. Morpeth JF, Williams MF. Vocal fold paralysis after anterior cervical discectomy and fusion. *Laryngoscope*. 2000;110:43-6.
24. Frempong-Boadu A, Houten JK, Osborn B, Opulencia J, Kells L, Guida DD, et al. Swallowing and speech dysfunction in patients undergoing anterior cervical discectomy and fusion: a prospective, objective preoperative and postoperative assessment. *J Spinal Disord Tech*. 2002;15:362-8.
25. Fountas KN, Kapsalaki EZ, Nikolakakos LG, Smisson HF, Johnston KW, Grigorian AA, et al. Anterior cervical discectomy and fusion associated complications. *Spine (Phila Pa 1976)*. 2007;32:2310-7.
26. Kahraman S, Sirin S, Erdogan E, Atabey C, Daneyemez M, Gonul E. Is dysphonia permanent or temporary after anterior cervical approach? *Eur Spine J*. 2007;16:2092-5.
27. Zeidman SM, Ducker TB, Raycroft J. Trends and complications in cervical spine surgery: 1989-1993. *J Spinal Disord*. 1997;10:523-6.
28. Gokaslan ZL, Bydon M, De la Garza-Ramos R, Smith ZA, Hsu WK, Qureshi SA, et al. Recurrent Laryngeal Nerve Palsy After Cervical Spine Surgery: A Multicenter AOSpine Clinical Research Network Study. *Global Spine J*. 2017;7(1 Suppl):53S-7S.
29. Tasiou A, Giannis T, Brotis AG, Siasios I, Georgiadis I, Gatos H, et al. Anterior cervical spine surgery-associated complications in a retrospective case-control study. *J Spine Surg*. 2017;3:444-59.
30. Dimopoulos VG, Chung I, Lee GP, Johnston KW, Kapsalakis IZ, Smisson HF 3rd, et al. Quantitative estimation of the recurrent laryngeal nerve irritation by employing spontaneous intraoperative electromyographic monitoring during anterior cervical discectomy and fusion. *J Spinal Disord Tech*. 2009;22:1-7.
31. Ryken TC, Heary RF, Matz PG, Anderson PA, Groff MW, Holly LT, et al. Techniques for cervical interbody grafting. *J Neurosurg Spine*. 2009;11:203-20.