

ULTRASONOGRAPHY IN CAUDAL INJECTIONS CAN REDUCE THE USE OF FLUOROSCOPY

Ali Güler¹, Yiğit Can Şenol¹, Resul Karadeniz¹, Ali Dalgıç²

¹Ankara Bilkent City Hospital, Clinic of Neurosurgery, Ankara, Turkey

²Ankara Medicana International Hospital, Clinic of Neurosurgery, Ankara, Turkey

ABSTRACT

Objective: We evaluated the differences between classical, fluoroscopy-guided caudal epidural steroid injection (CESI) and ultrasonography-guided CESI in terms of pain levels and the number of fluoroscopy shots administered in patients with lower lumbar disk herniation (L4-L5, L5-S1).

Materials and Methods: All procedures were performed in an operating room under sterile conditions. In total, 28 patients who underwent CESI using ultrasonography and 28 who underwent CESI using classical fluoroscopy were randomized and retrospectively compared in terms of the number of fluoroscopy shots administered. In the ultrasonographic group, the localization of the needle was confirmed by lateral fluoroscopic imaging after the procedure. In the classical fluoroscopy group, posteroanterior and lateral fluoroscopic images were used to guide the entry of the needle into the caudal canal from the skin entry point, advance the catheter in the canal, and administer the contrast material. The patients' pain levels before and after the procedure were self-evaluated using a visual analog scale.

Results: In the classical fluoroscopy group, the mean number of fluoroscopy shots was 7.07. In the ultrasonography group, it was 1.21. In the fluoroscopy group, the mean pain scores were 8.64±0.78 before, 3.10±1.13 immediately after, and 4.64±1.96 3 weeks after the procedure. In the ultrasonography group, the mean pain scores were 8.53±0.174 before, 3.10±0.238 immediately after, and 4.60±0.376 3 weeks after the procedure.

Conclusion: The use of ultrasonography in caudal injections reduces fluoroscopy exposure and, therefore, radiation exposure.

Keywords: Ultrasonography, caudal epidural steroid injection, fluoroscopy, radiation

INTRODUCTION

The most common causes of low back and leg pain are lumbar disk herniation, lumbar spondylosis, degenerative spondylolisthesis, and previous lumbar operation⁽¹⁾. In patients with low back and radicular pain due to a spinal pathology, epidural injection is known to reduce pain and improve functional status⁽²⁾. Caudal epidural steroid injection (CESI) can be considered a nonsurgical treatment method in patients with lower lumbar disk herniation (L4-L5, L5-S1) or lumbar spondylosis, in which pain cannot be relieved through medical treatment, rest, and physical therapy⁽³⁾. The caudal approach for epidural injection is easy to perform and relatively safe compared with the interlaminar and transforaminal approaches; thus, the risk of accidental dural puncture is reduced⁽⁴⁾. The caudal epidural intervention was first introduced as a block- and landmark-based blind technique. The blind procedure had a success rate of >96% in children; however, in adults, this rate was only 68-75%, even with experienced practitioners^(5,6). In epidural steroid injection (ESI), long-acting local anesthetic and corticosteroids with antiedema and anti-inflammatory effects are injected into

the epidural space⁽⁷⁾. The effectiveness of the injection depends on precise drug delivery to the putative site of pathology. The procedure is usually performed under fluoroscopy guidance, which has remarkably improved the success rate of CESI and is now considered the gold standard⁽⁸⁾. Fluoroscopic guidance helps confirm that the needle is correctly positioned and the drugs are properly injected into the epidural space. However, owing to the fluoroscopy-associated radiation hazard to patients and clinicians; it may not be applicable in daily practice. Intravascular injection during CESI has been reported in 3-14% of cases when conventional fluoroscopy is used, even after negative aspiration⁽⁹⁾.

The use of ultrasound guidance for conventional caudal epidural injections is increasing^(1,10,11). Ultrasound guidance enables the localization of the sacral hiatus and visualization of the sacrococcygeal ligament; it facilitates the detection of variations, thereby making injection easy and safe^(12,13). Ultrasound guidance can be used in almost any clinical setting; it is easy to learn and radiation-free. Very high success rates of 96.9-100% have been reported in ultrasound-guided CESI^(10,14). Ultrasound is not only effective for guiding needle placement

Address for Correspondence: Ali Güler, Ankara Bilkent City Hospital, Clinic of Neurosurgery, Ankara, Turkey

Phone: +90 505 400 76 29 **E-mail:** glerali@yahoo.com **Received:** 05.10.2022 **Accepted:** 27.11.2022

ORCID ID: orcid.org/0000-0002-8926-0313



but also can be used to predict CESI success and reduce the time spent on fluoroscopy-guided injections. We aimed to study the effect of ultrasonography on the number of fluoroscopy shots administered (radiation exposure) in fluoroscopy-guided CESI for lower lumbar disk herniation pathologies that do not require surgical intervention.

MATERIALS AND METHODS

We retrospectively and randomly screened patients with lower back and leg pain who had been diagnosed with lower lumbar disk herniation (L4-L5 and L5-S1), unilateral or bilateral radiculopathy for >3 months, and underwent the CESI procedure between June 2019 and June 2020. We excluded patients with rapidly progressive neurological deficit, cauda equina syndrome, motor weakness, previous spinal surgery, steroid use, and a history of allergy to steroids and iodinated contrast agents. Furthermore, we excluded patients with a skin infection at the site of intervention or multiple comorbidities (e.g., hypertension, diabetes mellitus, and ischemic heart disease).

The study was approved by the Ankara City Hospital Ethics Committee (decision no: E1/913/2020, date no: 16.07.2020) of the relevant institute. Informed written consent was obtained from all patients evaluated at an outpatient clinic. The patients' age and body mass index (BMI) data were recorded. A total of 28 patients underwent the ultrasound-guided CESI procedure, and 28 patients underwent classical fluoroscopy-guided CESI. The number of fluoroscopy shots administered during the procedure was noted and intergroup comparisons were performed. All procedures were performed in an operating room in sterile conditions. The CESI procedure was performed by placing a pillow under the abdomen of the patient lying in a prone position. The operation site was subsequently cleaned with an antiseptic solution containing povidone-iodine and covered in a sterile manner. Vascular access was opened using a 20-gauge Angiocath™ (Becton Dickinson, Franklin Lakes, NJ, USA), and isotonic solution [0.9% NaCl=saline fluid (SF)] was injected. Arterial blood pressure, pulse, peripheral oxygen saturation, and electrocardiogram were monitored.

An 18-gauge Tuohy spinal epidural needle was used in the classical fluoroscopy-guided CESI procedure. Fluoroscopy was performed (OEC Fluorostar C-8; GE Healthcare, Solingen, Germany) in stages of the localization of the spinal needle on the skin for confirming its entry into the caudal hiatus, advancing the catheter in the caudal hiatus, and confirming the location with 1-2 mL of contrast material (Omnipaque; Medikim, Istanbul, Turkey). Posteroanterior and lateral images were obtained (Figure 1), and the number of fluoroscopy shots was noted. Subsequently, the sacral hiatus was determined, and local anesthesia (lidocaine, 2 mL) was applied using a 27-gauge dental-tipped (Germany) needle. Through separate injectors, the following were administered via the catheter as a 10 mL mixture: 1 mL (40 mg) methylprednisolone acetate as steroid; 40 mg/mL Depo-Medrol® (Pfizer, New York, NY, USA) with 5 mL

(25 mg) bupivacaine as a local anesthetic; and Marcaine (0.5 flacons; Eczacıbaşı, Turkey), diluted with 5 mL of 0.9% NaCl=SF. The needle was inserted up to the S3 level for proper dissemination of the drug. A Christmas tree-like appearance was observed in all patients, resembling a contrast dye distribution.

For ultrasound-guided CESI, we used the Aplio 500 ultrasound machine (Toshiba, Tokyo, Japan). After sterile wrapping of the convex probe, an axial image was first obtained in the midline; the two hypochoic sacral corns, sacrococcygeal ligament, and sacrum surface were visualized. The sacral hiatus was visualized between the sacrococcygeal ligament and sacral surface (Figure 2). The sacral canal is a triangular opening at the caudal end of the sacrum, bound laterally by two sacral corns. While the probe was on the sacral hiatus, it was rotated 90° longitudinally and the sacral base, sacrococcygeal ligament, and sacral hiatus were observed (Figure 3). The skin was then penetrated by an 18-gauge spinal needle under ultrasound guidance. As soon as the sacral hiatus was believed to have been entered, a lateral fluoroscopic image was obtained; thus, it was confirmed that the needle was in the sacral hiatus (Figure 4). When the needle was at the point of passing the sacrococcygeal ligament, without further advancement, a mixture of steroid, local anesthesia, and saline was administered at the same dose as in the other method. In both methods, negative pressure was applied to the needle and the absence of vascular leakage was confirmed. Although contrast material was administered in the fluoroscopy-guided procedure, it was not administered in the ultrasound-guided procedure. After the procedure, each patient was transferred to a postoperative follow-up room and their hemodynamic parameters were monitored for 30 min; they were subsequently moved to the ward. The patients were followed up for 2 h before being discharged and were informed about any possible complications. The patients evaluated their pain levels before, during, immediately after, and 3 weeks after the injection using a visual analog scale (VAS), with the absence of pain scoring 0 and severe pain scoring 10 on the VAS.

Statistical Analysis

Statistical Package for the Social Sciences, version 23.0 (IBM Corporation, Armonk, NY, USA), was used for statistical analyses. We tested for normality using the Shapiro-Wilk test. Descriptive statistics are reported as means with standard deviations, medians with ranges, or frequencies with percentages. We calculated 95% confidence intervals. Intergroup comparisons were performed using Student's t-test or Mann-Whitney U test. Outcomes at baseline and follow-up were analyzed using a two-way repeated-measures analysis of variance. Statistical significance was set at $p < 0.05$.

RESULTS

This study included 56 patients-28 received classical fluoroscopic CESI, and the remaining 28 received ultrasound guidance-assisted CESI. In the classical fluoroscopic group,

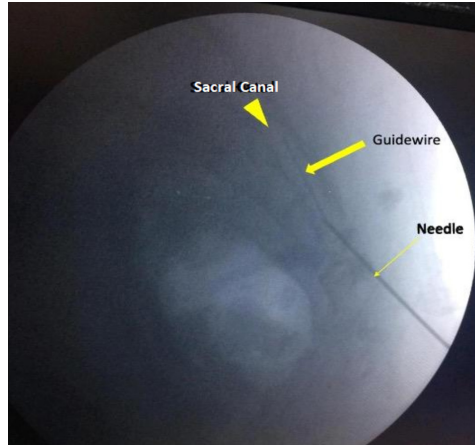


Figure 1. Lateral fluoroscopic view of catheter advancement in fluoroscopic CESI
 CESI: Caudal epidural steroid injection

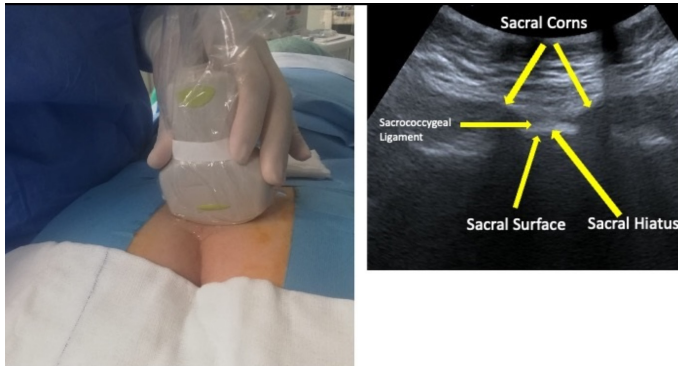


Figure 2. In the axial view of the convex ultrasound probe, two hypoechoic sacral corns, the sacrococcygeal ligament, and the sacrum surface were visualized. The sacral hiatus was visualized between the sacrococcygeal ligament and sacral surface

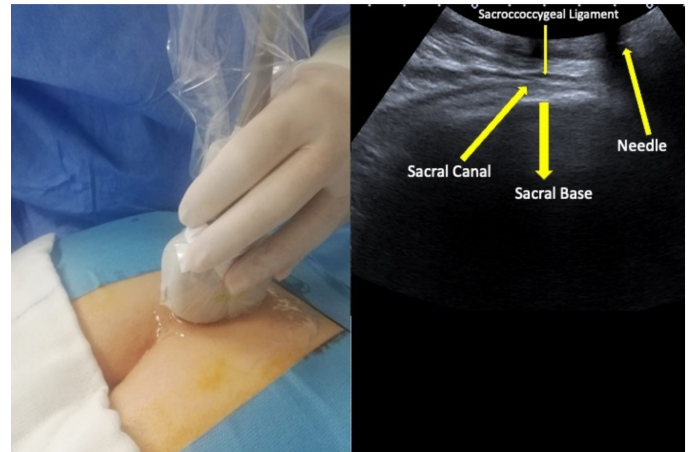


Figure 3. While the probe was on the sacral hiatus, it was rotated 90° longitudinally and the sacral base, sacrococcygeal ligament, and sacral hiatus were observed

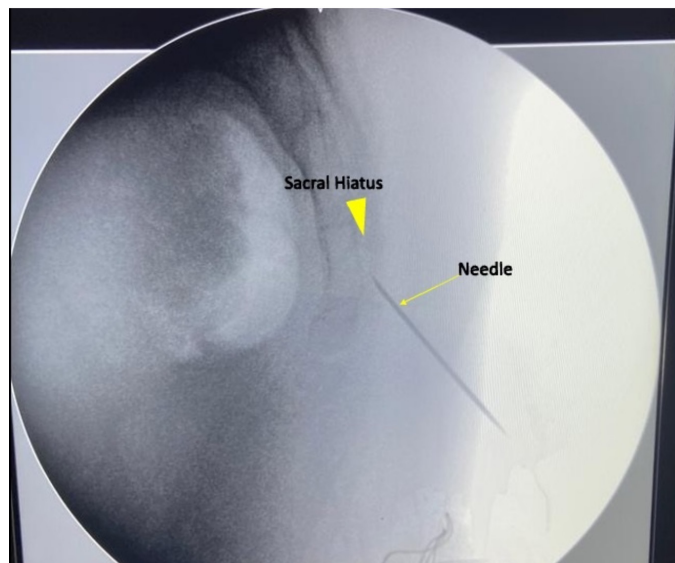

Figure 4. Lateral fluoroscopic image. It was confirmed that the needle was in the sacral hiatus

there were 10 men and 18 women (age, 48.53 ± 10.18 years; BMI, 24.96 ± 1.02 kg/m²; mean symptom duration, 18.3 ± 12.85 months). Lumbar disk pathology was at L5-S1 in 11 patients, L4-L5 in 5, and both L5-S1 and L4-L5 in 9. Nine patients had a lumbar narrow canal attached to the disk. The mean number of fluoroscopy shots administered was 7.07 ± 0.76 (Table 1). The mean VAS pain scores were 8.64 ± 0.78 before, 3.10 ± 1.13 immediately after ($p < 0.001$), and 4.64 ± 1.96 ($p < 0.001$) 3 weeks after the procedure (Table 1).

In the ultrasound guidance-assisted group, there were 12 men and 16 women (age, 49.35 ± 10.75 years, BMI, 24.36 ± 1.66 kg/m²; mean symptom duration, 22.5 ± 17.64 months). Lumbar disk pathology was at L5-S1 in 10 patients, L4-L5 in four patients, and at both L5-S1 and L4-L5 in five patients. Lumbar narrow canal attached to the disk was present in five patients. The mean number of fluoroscopy shots administered was 1.21 ± 0.41 ($p < 0.001$) (Table 1). Mean VAS pain scores were 8.53 ± 0.174 before, 3.10 ± 0.238 immediately after ($p < 0.001$), and 4.60 ± 0.376 ($p < 0.001$) 3 weeks after the procedure (Table 1).

No significant difference was observed between the two groups in terms of mean age and sex (Table 1). The VAS pain scores after the procedure were significantly lower in both groups than before it ($p < 0.001$) (Table 2). Furthermore, no significant difference was noted in the improvement of VAS pain scores after the procedure between the two groups (Table 3). The mean number of fluoroscopy shots was significantly lower in the ultrasound-assisted group than in the classical fluoroscopic group ($p < 0.001$).

In one patient who received ultrasound-assisted CESI, the caudal hiatus entrance was located and medication was administered using fluoroscopy because axial imaging with the ultrasound probe could not be technically performed owing to the patient's gluteal pathology. Therefore, this patient, who received a high number of fluoroscopy shots, was not included in the evaluation. Similarly, two patients who underwent ultrasound-assisted CESI could not be confirmed using fluoroscopy because of an unexpected malfunction of the fluoroscopy device. The procedure was considered successful; the patients' pain scores decreased considerably after drug administration. However, these two patients were not included in the evaluation. No complications were observed in either group.

DISCUSSION

The mean number of fluoroscopy shots administered to patients was significantly lower in the ultrasound-assisted group than in the classical fluoroscopic group. Thus, the ultrasound group received less radiation exposure than the fluoroscopy group. In both groups, there was an improvement in VAS pain scores immediately and 3 weeks after the procedure compared with the pre-procedure score. No significant intergroup difference was noted in terms of the improvements.

In caudal epidural injection, the sacral hiatus is a crucial bone structure with a diameter of < 3.7 mm apically. This structure

has been associated with difficulty in inserting a needle into the caudal epidural space using the blind technique⁽¹⁵⁾. Challenges are encountered when ultrasound is used to guide needle insertion in patients with a sacral hiatus anteroposterior diameter of < 1.6 mm⁽¹¹⁾. In our study, there was no failure during needle insertion in either group.

Several studies have reported that ultrasonography is an effective tool for the CESI procedure because it is easy to use in the evaluation of musculoskeletal diseases, provides real-time images, and does not cause radiation exposure^(10,12,16). Hazra et al.⁽¹⁷⁾ reported that needle insertion time was significantly shorter using ultrasound guidance than using fluoroscopy guidance.

Needle placement in the (fluoroscopic) control subjects was performed with complete accuracy in the ultrasound-assisted procedures of our study. We did not use contrast materials in the fluoroscopic controls; we used the fluoroscopic controls only to confirm the location of the needle before drug administration. The contrast agent used in fluoroscopy to examine the distribution of the administered drug can cause various side effects such as nausea, vomiting, extensive urticaria, bronchospastic reaction, hypotension, tachycardia, and anaphylactic reactions^(18,19). Other serious complications include lower extremity myoclonic spasms and tonic seizure, leading to status epilepticus; rhabdomyolysis and disseminated intravascular coagulation have also been reported⁽²⁰⁾. In addition to the side effects of the contrast medium, cost should also be considered. We did not use contrast material in the ultrasound guidance group; no complications were observed during the procedure or follow-ups. There is a minimal risk of intravascular injection or dural puncture when the injection is performed immediately after penetration into the sacrococcygeal ligament. Doo et al.⁽²¹⁾ examined the effect of needle depth in caudal injection under ultrasound guidance by comparing two groups as follows: One with caudal injection performed using a traditional method after the needle was advanced 1 cm into the sacral canal, the other in which injection was performed using a new method immediately after penetration into the sacrococcygeal ligament. Subsequently, fluoroscopy with contrast material was obtained to evaluate the epidural spread of the injected materials and monitor possible complications. The incidence of intravascular injection was 24% in the first group and 0% in the second. The authors concluded that the new caudal epidural injection technique was a safe alternative to the traditional technique, with a higher success rate and lower risk of accidental intravascular injection. Their study also reported that the use of contrast to verify the accuracy of needle position in the CESI procedure was not necessary and did not confer additional benefits when performed by experienced clinicians. In our study, the injection was performed under ultrasound guidance when the needle was at the point of penetrating the sacrococcygeal ligament at an angle of approximately 45° in the position preceding advancement into the sacral canal. No

Table 1. Comparison of patients' demographics, number of fluoroscopy shots administered, and VAS before and after the procedure. Changes in the VAS score before, immediately after, and 3 weeks after the procedure

	Ultrasound (n=28)	Fluoroscopy (n=28)	p-value
Age (± SD)	49.35±10.75	48.53±10.18	0.863
Gender			
Female (n; %)	16; 57.1	18; 64.3	0.392
BMI (± SD)	24.36±1.66	24.96±1.02	0.254
Duration (month)	22.5±17.64	18.3±12.85	0.478
Level			
L4-L5 (n; %)	4; 14.3	5; 17.9	0.984
L5-S1 (n; %)	10; 35.7	11; 39.3	
Midline (n; %)	4; 14.3	4; 14.3	
Disc + narrow channel (n; %)	5; 17.9	9; 16.1	
L45 + L4-L5 + L5-S1 (n; %)	5; 17.9	9; 16.1	
Number of shots	1.21±0.41	7.07±0.76	<0.001*
VAS before	8.53±0.174	8.64±0.78	0.734
After VAS after	3.10±0.238	3.10±1.13	0.823
VAS 3 rd week	4.60±0.376	4.64±1.96	0.927

*p<0.05

SD: Standard deviation, BMI: Body mass index, VAS: Visual analog scale pain score

Table 2. Changes in the VAS score before, immediately after, and 3 weeks after the procedure

	Ultrasound	p-value	Fluoroscopy	p-value
VAS before	8.53±0.174	-	8.64±0.78	-
After VAS	3.10±0.238	<0.001	3.10±1.13	<0.001
VAS 3 rd week	4.60±0.376	<0.001	4.64±1.96	<0.001

SD: Standard deviation; BMI: Body mass index, VAS: Visual analog scale pain score

Table 3. Comparison of improved VAS scores between the two groups

	Ultrasound mean difference	Fluoroscopy mean difference	p-value
VAS before-after	5.41±0.29	5.53±0.28	0.810
VAS before-3 rd week	3.92±0.39	4.00±0.39	0.961

VAS: Visual analog scale pain score

contrast material was used in the fluoroscopic control and no complications were observed.

In a study by Chen et al.⁽¹⁰⁾, the sacral hiatus was accurately positioned by ultrasound in 70 patients; then, the caudal epidural needle was successfully inserted into the sacral hiatus and caudal epidural space, which was subsequently confirmed via contrast agent fluoroscopy. An accuracy of 100% in needle placement was reported. In our study, we also report 100% accuracy in needle placement performed with ultrasound guidance. Ultrasonography can be as effective as fluoroscopy in preventing complications during caudal epidural injection, except for intravascular and intrathecal injections⁽²²⁾. Naidoo et al.⁽²³⁾ investigated the value of using contrast as an additional aid to verify the accuracy of needle placement for intraoperative image intensifier-guided caudal epidural injections. Correct needle placement on the first attempt was confirmed in 100% of cases. These results show that an experienced surgeon can

accurately place the needle in caudal epidural injections using image intensification, without contrast.

Although fluoroscopy is the gold standard for confirming needle placement during the CESI procedure, radiation exposure is a major concern when fluoroscopic images are obtained^(24,25).

The presence of an association between radiation and cancer is well known; however, the long-term effects of exposure to low radiation doses-and the known safe dose-are not completely known^(26,27). Ionizing radiation has two effects at the cellular level. First, in deterministic effects, a threshold for the occurrence of damage exists and the amount of damage increases as the dose increases. In these terms, skin injuries have been a major concern in a fluoroscopy-guided intervention⁽¹⁰⁾. Second, in cytostatic effects, the radiation effect is "all or nothing"; there is no threshold, and the effects are likely to occur even at the lowest dose levels. During medical imaging, the cytostatic effect is more probable. Chronic effects are

more likely to be the result of long-term, low-dose exposure. It is well known that cumulative exposure to radiation increases the risk of adverse health effects such as genetic effects, cataracts, circulatory diseases, and cancer^(26,27).

The radiation dose is a measure of the energy stored in tissue as a result of the interaction between radiation and living tissue, measured in units of radiation absorbed dose (RAD), roentgen equivalent man (REM), grays (Gy), and sieverts (Sv). The gray unit (the international unit for RAD) represents the amount of radiation that causes 1 J energy absorption in 1 kg irradiated material (1 RAD=1 REM=1000 mRAD=1000 mREM=0.01 Gy). The international unit of measurement for the biological effects of X-rays on the human body is the Sv: 1 Sv=100 RAD (i.e., 1 Sv=1 Gy=100 RAD=100 REM or 1 REM=1 RAD=0.001 Sv).

The maximum dose for radiation workers is 20 mSv/year for five consecutive years and 50 mSv/year for a single year. For the public, the maximum dose is 10 mSv/year for five consecutive years and 5 mSv/year for a single year⁽²⁸⁾. To avoid radiation-induced skin damage, the recommended threshold for exposure is 2 Gy and the annual exposure limit is 50 mSv⁽²⁹⁾.

As mentioned earlier, radiation is known to be associated with cancer; however, the long-term effects of exposure to low radiation doses as well as the known safe dose remain unknown. In Turkey and worldwide, the “as low as reasonably achievable” (ALARA) principle is used to reduce radiation exposure⁽³⁰⁾. At present, to the best of our knowledge, there is no universally accepted guideline for minimizing radiation exposure in the operating room; the cumulative radiation exposure of operators is not known. The operators must follow simple radiation safety rules to minimize their exposure, such as increasing their distance from the radiation source; reducing overall exposure time; and protecting sensitive areas with lead aprons, thyroid shields, lead goggles, and lead gloves. A study by Vural et al.⁽³¹⁾ reported that 90% of operating room workers had been exposed to fluoroscopy in the past year; 44% were exposed to fluoroscopy more than once per week. Even very low radiation doses (e.g., 0.001 RAD) are carcinogenic and exert negative effects on the skin, eyes, gonads, and blood cells. Wearing a lead apron is an important protection against radiation; a lead thickness of 0.5 reduces radiation exposure by 97-99%⁽³²⁾. The annual average dose received by workers exposed to radiation should be between 1-5 mSv. When fluoroscopy machine operators use radiation protection methods, their radiation dose can be limited to <1 mSv per year. Notably, each dose can have a harmful effect. Hence, most doctors believe that even a single radiological X-ray carries a small risk. Therefore, the ALARA principle is accepted as the gold standard in radiology practice.

The dose area product (DAP) and kerma area product (KAP) are radiation dose monitoring methods used in radiographic and fluoroscopic studies. They provide indications of the radiation dose received by a patient. DAP is calculated as the product of the dose and beam area (Gy/cm²). It can be divided by the area of exposure (cm²) to determine the event total exposure

(air kerma) of that area, which can be used to calculate the skin's accumulated dose. It is important to measure this in interventional and fluoroscopic procedures because of the risk of deterministic effects.

In a previous study involving 228 patients, KAP and fluoroscopy time (FT) were recorded in 47 patients to whom lumbosacral ESI was administered. It was found that the longer the fluoroscopy period, the longer was the KAP in both transforaminal and caudal ESIs. FT was longer for transforaminal than for caudal ESIs. However, the KAP of transforaminal ESI was less than that of caudal ESI after correction for the length of FT⁽³³⁾.

Kim et al.⁽³⁴⁾ evaluated radiation exposure and response time during various ESI procedures (caudal, interlaminar, and transforaminal) according to surgical seniority (senior faculty, junior faculty, and trainee) and fluoroscopy type [continuous monitoring (CM) or intermittent monitoring (IM)]. DAP, FT, and intervention time during lumbar ESI were compared. Radiation exposure was found to be within the established safety limits during lumbar ESIs under CM, depending on practitioners and methods. With an experienced practitioner, IM resulted in less radiation exposure than CM. IM is reported to be effective at reducing radiation exposure and appears to be preferable to CM. Cushman et al.⁽³⁵⁾ studied the relationship among BMI, FT, and radiation dose during lumbar ESI and found that fluoroscopy radiation dose and FT during lumbar ESIs increased in older patients and those with a high BMI; the presence of a trainee did not affect FT. The present study found no difference in terms of BMI between the two experimental groups.

Tecer et al.⁽³⁶⁾ investigated differences in the radiation exposure of patients between the oblique and posteroanterior views. Data regarding the total KAP, procedure duration, and FT were obtained from medical records. The authors concluded that radiation risk does not vary between these approaches.

A previous study found that the duration of fluoroscopy exposure (for various interventional procedures) in educational settings such as university hospitals is significantly higher than in private practice settings. Significant differences were also found among physicians in the same university setting⁽³⁷⁾.

Hwang et al.⁽³⁸⁾ conducted a study to predict and compare the radiation exposure of patients during transforaminal fluoroscopy-guided ESI at different vertebral levels. The patients were categorized into three groups according to the injected lumbosacral nerve level (L2-L4, L5, or S1); FT and DAP were recorded. After correcting for FT, DAP was found to be significantly lower at S1 than that at either L2-L4 or L5.

When there is direct physician control of the fluoroscopy unit in fluoroscopy-guided lumbar spinal interventions, the FT required is significantly shorter (6 seconds), which results in a lower radiation dose (DAP, 0.59 Gy·cm²)⁽³⁹⁾.

A previous study compared the safety of reducing radiation exposure via high-dose CM fluoroscopy, medium-dose pulsed fluoroscopy (eight pulses per second), and low-dose pulsed fluoroscopy (one pulse per second) in 231 patients receiving

Braun lumbar transforaminal ESI. Pulsed fluoroscopy reduced the radiation dose by up to 72.1% without causing any significant adverse events; thus, it should be considered the initial fluoroscopic for reducing radiation exposure⁽⁴⁰⁾. In our study, we used pulsed fluoroscopy to reduce radiation exposure. The use of ultrasound guidance reduced the number of fluoroscopy shots administered by approximately 80%. Approximately 250-300 deaths occur per year in the United Kingdom due to cancer arising directly from medical radiation exposure⁽⁴¹⁾.

A study by Botwin et al.⁽⁴²⁾ found that the physician's radiation exposure is within safety limits when appropriate techniques are used. In our study, we used a lead apron during CESI in the classical fluoroscopic group. In the ultrasound guidance-assisted group, fluoroscopy was used only to confirm that the needle was in the caudal canal; all personnel in the operating room were protected from the fluoroscopy device by maintaining a 5m distance from it or leaving the room. Because radiation exposure is cumulative over a lifetime, it is necessary to employ basic principles of radiation protection, including maximizing distance from the radiation source, using shielding materials, and minimizing exposure time. Even if protective clothing is used (e.g., lead apron, lead goggles, and radiation-attenuating gloves), the radiation hazard is still a significant concern for the radiologists who perform interventions. Regardless of the protection measures taken, it is never possible to reset radiation exposure. The most effective prevention of radiation exposure may be a reduction of the use of fluoroscopy (e.g., using ultrasonography).

Study Limitations

Although our study was limited in measuring radiation exposure by the number of fluoroscopy shots (rather than direct measurement), we consider that the radiation dose was minimal.

CONCLUSION

Modern ultrasonography enables good visualization of anatomical structures in real-time and avoids the hazards posed by radiation and iodinated contrast media. We believe that CESI with ultrasound guidance is effective for acute and chronic low back pain with the advantage of minimal radiation exposure. Long-term, follow-up and comparative studies with larger numbers of patients are required for evaluating the efficacy of CESI.

Acknowledgments: The authors would like to thank Enago (<http://www.enago.com>) for the English language review. "Preparation for publication of this article is partly supported by Turkish Neurosurgical Society".

Ethics

Ethics Committee Approval: The study was approved by the Ankara City Hospital Ethics Committee (decision no: E1/913/2020, date no: 16.07.2020).

Informed Consent: Informed written consent was obtained from all patients evaluated at an outpatient clinic.

Peer-review: Externally and internally peer-reviewed.

Authorship Contributions

Surgical and Medical Practices: A.G., A.D., Concept: A.G., A.D., Design: A.G., A.D., Data Collection or Processing: A.G., Y.C.Ş., R.K., Analysis or Interpretation: A.G., Literature Search: A.G., Y.C.Ş., R.K., Writing: A.G.

Conflict of Interest: The authors have no conflicts of interest to declare.

Financial Disclosure: The authors declared that this study received no financial support.

REFERENCES

1. Manchikanti L, Cash KA, McManus CD, Pampati V, Fellows B. Results of 2-year follow-up of a randomized, double-blind, controlled trial of fluoroscopic caudal epidural injections in central spinal stenosis. *Pain Physician*. 2012;15:371-84.
2. Leem JG. Epidural steroid injection: a need for a new clinical practice guideline. *Korean J Pain*. 2014;27:197-9.
3. Karppinen J, Ohinmaa A, Malmivaara A, Kurunlahti M, Kyllönen E, Pienimäki T, et al. Cost effectiveness of periradicular infiltration for sciatica: subgroup analysis of a randomized controlled trial. *Spine (Phila Pa 1976)*. 2001;26:2587-95.
4. Lee JW, Myung JS, Park KW, Yeom JS, Kim KJ, Kim HJ, et al. Fluoroscopically guided caudal epidural steroid injection for management of degenerative lumbar spinal stenosis: short-term and long-term results. *Skeletal Radiol*. 2010;39:691-9.
5. Orme RM, Berg SJ. The 'swoosh' test--an evaluation of a modified 'whoosh' test in children. *Br J Anaesth*. 2003;90:62-5.
6. Stitz MY, Sommer HM. Accuracy of blind versus fluoroscopically guided caudal epidural injection. *Spine (Phila Pa 1976)*. 1999;24:1371-6.
7. Loizides A, Peer S, Plaikner M, Spiss V, Galiano K, Obernauer J, et al. Ultrasound-guided injections in the lumbar spine. *Med Ultrason*. 2011;13:54-8. Erratum in: *Med Ultrason*. 2011;13:178.
8. Barham G, Hilton A. Caudal epidurals: the accuracy of blind needle placement and the value of a confirmatory epidurogram. *Eur Spine J*. 2010;19:1479-83.
9. Sullivan WJ, Willick SE, Chira-Adisai W, Zuhosky J, Tyburski M, Dreyfuss P, et al. Incidence of intravascular uptake in lumbar spinal injection procedures. *Spine (Phila Pa 1976)*. 2000;25:481-6.
10. Chen CP, Tang SF, Hsu TC, Tsai WC, Liu HP, Chen MJ, et al. Ultrasound guidance in caudal epidural needle placement. *Anesthesiology*. 2004;101:181-4.
11. Chen CP, Wong AM, Hsu CC, Tsai WC, Chang CN, Lin SC, et al. Ultrasound as a screening tool for proceeding with caudal epidural injections. *Arch Phys Med Rehabil*. 2010;91:358-63.
12. Klocke R, Jenkinson T, Glew D. Sonographically guided caudal epidural steroid injections. *J Ultrasound Med*. 2003;22:1229-32.
13. Piraccini E. Sonographic guidance for caudal epidural steroid injection: a diagnostic tool. *Turk J Anaesthesiol Reanim*. 2021;49:484-5.
14. Blanchais A, Le Goff B, Guillot P, Berthelot JM, Glemarec J, Maugars Y. Feasibility and safety of ultrasound-guided caudal epidural glucocorticoid injections. *Joint Bone Spine*. 2010;77:440-4.
15. Kim YH, Park HJ, Cho S, Moon DE. Assessment of factors affecting the difficulty of caudal epidural injections in adults using ultrasound. *Pain Res Manag*. 2014;19:275-9.
16. Jee H, Lee JH, Kim J, Park KD, Lee WY, Park Y. Ultrasound guided selective nerve root block versus fluoroscopy guided transforaminal block for the treatment of radicular pain in the lower cervical spine: a randomized, blinded, controlled study. *Skeletal Radiol*. 2013;42:69-78.

17. Hazra AK, Bhattacharya D, Mukherjee S, Ghosh S, Mitra M, Mandal M. Ultrasound versus fluoroscopy-guided caudal epidural steroid injection for the treatment of chronic low back pain with radiculopathy: a randomised, controlled clinical trial. *Indian J Anaesth.* 2016;60:388-92.
18. Andreucci M, Solomon R, Tasanarong A. Side effects of radiographic contrast media: pathogenesis, risk factors, and prevention. *Biomed Res Int.* 2014;2014:741018.
19. Goodman BS, Posecion LW, Mallempati S, Bayazitoglu M. Complications and pitfalls of lumbar interlaminar and transforaminal epidural injections. *Curr Rev Musculoskelet Med.* 2008;1:212-22.
20. Alimohammadi H, Abdalvand A, Safari S, Mazinianian A. Status epilepticus after myelography with iohexol (Omnipaque). *Am J Emerg Med.* 2012;30:2092.e1-3.
21. Doo AR, Kim JW, Lee JH, Han YJ, Son JS. A comparison of two techniques for ultrasound-guided caudal injection: the influence of the depth of the inserted needle on caudal block. *Korean J Pain.* 2015;28:122-8.
22. Kao SC, Lin CS. Caudal epidural block: an updated review of anatomy and techniques. *Biomed Res Int.* 2017;2017:9217145.
23. Naidoo K, Alazzawi S, Montgomery A. The use of contrast in caudal epidural injections under image intensifier guidance: is it necessary? *Clin Orthop Surg.* 2017;9:190-2.
24. Murakibhavi VG, Khemka AG. Caudal epidural steroid injection: a randomized controlled trial. *Evid Based Spine Care J.* 2011;2:19-26.
25. Park Y, Lee JH, Park KD, Ahn JK, Park J, Jee H. Ultrasound guided vs. fluoroscopy guided caudal epidural steroid injection for the treatment of unilateral lower lumbar radicular pain: a prospective, randomized, single blind clinical study. *Am J Phys Med Rehabil.* 2013;92:575-86.
26. Huhn A, de Oliveira Vargas MA, de Melo JAC, Gelbcke FL, Ferreira ML, Lança L. Implementation of a radiation protection program: opinion of the health team working in a radiology service. *Texto Contexto Enferm.* 2017;26:e5370015.
27. Salvia JC, de Moraes PR, Ammar TY, Schwartzmann CR. Fluoroscopy duration in orthopedic surgery. *Rev Bras Ortop.* 2015;46:136-8.
28. International Commission on Radiological Protection. Available from: URL: <https://www.icrp.org/>
29. Bolus NE. Basic review of radiation biology and terminology. *J Nucl Med Technol.* 2001;29:67-73; test 76-7.
30. Kaplan DJ, Patel JN, Liporace FA, Yoon RS. Intraoperative radiation safety in orthopaedics: a review of the ALARA (As low as reasonably achievable) principle. *Patient Saf Surg.* 2016;10:27.
31. Vural F, Fil Ş, Çiftçi S, Dura AA, Yıldırım F, Patan R. Radiation safety in operating units; knowledge, attitude and behaviors of operating room staffs. *Balikesir Health Sci J.* 2012;1:131-6.
32. Çeçen GS, Gülabi D, Pehlivanoğlu G, Bulut G, Bekler H, Asil K. Radiation in the orthopedic operating theatre. *Acta Orthop Traumatol Turc.* 2015;49:297-301.
33. Kim SJ, Lee MH, Lee SW, Chung HW, Lee SH, Shin MJ. Radiation exposure for fluoroscopy-guided lumbosacral epidural steroid injections.comparison of the transforaminal and caudal approaches. *J Spinal Disord Tech.* 2014;27:E37-40.
34. Kim S, Shin JH, Lee JW, Kang HS, Lee GY, Ahn JM. Factors affecting radiation exposure during lumbar epidural steroid injection: a prospective study in 759 patients. *Korean J Radiol.* 2016;17:405-12.
35. Cushman D, Mattie R, Curtis B, Flis A, McCormick ZL. The effect of body mass index on fluoroscopic time and radiation dose during lumbar transforaminal epidural steroid injections. *Spine J.* 2016;16:876-83.
36. Tecer D, Yasar E, Adiguzel E, Taskaynatan MA, Balaban B, Tan AK. Comparison of lumbosacral transforaminal epidural steroid injection techniques in terms of radiation safety. *Pain Manag.* 2017;7:113-8.
37. Zhou Y, Singh N, Abdi S, Wu J, Crawford J, Furgang FA. Fluoroscopy radiation safety for spine interventional pain procedures in university teaching hospitals. *Pain Physician.* 2005;8:49-53.
38. Hwang YM, Lee MH, Kim SJ, Lee SW, Chung HW, Lee SH, et al. Comparison of radiation exposure during fluoroscopy-guided transforaminal epidural steroid injections at different vertebral levels. *Korean J Radiol.* 2015;16:357-62.
39. Choi MH, Choi BC, Jung SE, Byun JY. Factors related to radiation exposure during lumbar spine intervention. *J Korean Med Sci.* 2016;31 Suppl 1(Suppl 1):S55-8.
40. Braun E, Sack A, Sayed D, Manion S, Hamm B, Brimacombe M, et al. Reducing radiation exposure in lumbar transforaminal epidural steroid injections with pulsed fluoroscopy: a randomized, double-blind, controlled clinical trial. *Pain Physician.* 2018;21:53-60.
41. Royal College of Radiologists and National Radiological Protection Board (NRPB). Patient dose reduction in diagnostic radiology. 1990;1:3.
42. Botwin KP, Thomas S, Gruber RD, Torres FM, Bouchlas CC, Rittenberg JJ, et al. Radiation exposure of the spinal interventionalist performing fluoroscopically guided lumbar transforaminal epidural steroid injections. *Arch Phys Med Rehabil.* 2002;83:697-701.